

# Mycotoxins in poultry - External signs can give a hint



## Part 4: Paleness

*By Dr. Inge Heinzl, Editor and Marisabel Caballero, Global Technical Manager Poultry*

We already showed bad feathering, mouth and beak lesions, bone issues, and foot pad lesions as signs of mycotoxin contamination in the feed, but there is another indicator: paleness. Paleness can signify a low count of red blood cells resulting from blood loss or inadequate production of these cells. Other possibilities are higher bilirubin levels in the blood due to an impaired liver, leading to jaundice or missing pigmentation.



Hen with pale comb and wattles (adapted

# The mycotoxins mainly causing anemia are Aflatoxins, Ochratoxin, DON, and T-2 toxin

Anemia can be diagnosed using parameters such as red blood cell count, hemoglobin levels, and hematocrit/packed cell volume (PCV). Numerous studies have examined the impact of mycotoxins on hematological parameters. They reveal their propensity to affect red blood cell production by impairing the function of the spleen and inducing hematological alterations. On the other hand, anemia can be caused by blood loss. Due to affecting coagulation factors, mycotoxins can lead to internal hemorrhages. The gut wall damage, probably due to secondary infections such as coccidiosis and necrotic enteritis, can entail bloody diarrhea in various animal species.

## Impact on the production of blood cells

Low values of blood parameters such as red blood cells, hemoglobin, and hematocrit can result from inadequate production due to impacted production organs. The World Health Organization ([WHO, 1990](#)) and European Commission ([European Commission, 2001](#)) have identified hematopoietic tissues as targets for necrosis caused by T-2 toxin. Chu (2003) even stated that “the major lesion of T-2 toxin is its devastating effect on the hematopoietic system in many mammals, including humans”. [Pande et al. \(2006\)](#) suggested that reduced hemoglobin values result from decreased protein synthesis due to mycotoxin contamination, a notion supported by [Pronk et al. \(2002\)](#), who described trichothecenes as potent inhibitors of protein, DNA, and RNA synthesis, particularly affecting tissues with high cell division rates. Additionally, the [European Commission \(2001\)](#) highlighted the sensitivity of red blood cell progenitor cells (in this trial, the cells of mice, rats, and humans) to the toxic effects of T-2 and HT-toxins. DAS also seems to attack the hematopoietic system, as shown in humans ([WHO, 1990](#)). A further cause for anemia might be low feed intake or nutrient absorption, which inhibits adequate iron absorption and leads to iron deficiency. In their case report, [Bozzo et al. \(2023\)](#) assumed that renal failure and a resulting impaired excretion capacity caused by OTA might even increase the half-life of the toxins. This would enhance their effects on their target organs, such as the liver and bone marrow, and lead to anemia.

Several studies utilizing different animal species and mycotoxin dosages have been conducted to assess the effects of Aflatoxins, Ochratoxin, and T-2 Toxin on hematological parameters. The following table provides a summary of some of these studies.

Animal species	Dosage	Impact	Reference
<b>T-2 Toxin and other Trichothecenes</b>			
Broilers	T-2 - 0, 1, 2, and 4 mg T-2 toxin/kg n=30 per group	Significant reduction in hemoglobin at 1, 2, and 4 ppm; PCV significantly reduced at 4 ppm	<a href="#">Pande et al., 2006</a>
Broilers	T-2 - 0 and 4 mg/kg diet n=60 per group	Decrease in hemoglobin, mean corpuscular volume, and mean corpuscular hemoglobin concentration	<a href="#">Kubena et al., 1989a</a>
Broilers	4, 16, 50, 100, 300 ppm for seven days n=5-20 chickens per group	Anemia; significant reduction of hematocrit (50 and 100 ppm); survivors had atrophied lymphoid organs and were anemic	<a href="#">Hoerr et al., 1982</a>

Yangzhou goslings	0, 0.2, 0.4, 0.6, 0.8, 1.0, 2.0 mg/kg; n=6 per group	Red blood cell count decreased in the 2.0 mg/kg group along with an increase in mean corpuscular hemoglobin (p<0.05) and reduced mean platelet volume (P<0.05)	<a href="#">Gu et al., 2023</a>
Broilers	2 ppm; 32 birds per group	Anemia, as indicated by significantly (P<0.05) lower total erythrocyte count (TEC) values, lower hemoglobin levels, and packed cell volume; additional thrombocytopenia could be the cause of bleeding	<a href="#">Yohannes et al., 2013</a>
<b>DON</b>			
Broilers	5 and 15 mg/kg of feed for 42 days	Decrease in erythrocytes, mean corpuscular volume (MCV), and mean corpuscular hemoglobin concentration (MCHC) at 15 mg/kg; decrease in hematocrit and hemoglobin at both levels of DON.	<a href="#">Riahi, 2021</a>
Piglets	0.6 mg/kg and 2.0 mg/kg	Significant decrease in mean corpuscular volume	<a href="#">Modrá et al., 2013</a>
Broilers	16 mg/kg diet n=60 per group	Significant decrease in mean corpuscular volume	<a href="#">Kubena et al., 1989c</a>
<b>Ochratoxin</b>			
Broilers	2 mg/kg diet singly or combined with DAS 6 mg/kg	Reduced mean corpuscular hemoglobin values	<a href="#">Kubena et al., 1994</a>
Broilers	2 mg/kg diet	Significant decrease in hemoglobin, hematocrit, mean corpuscular volume and mean corpuscular hemoglobin concentration	<a href="#">Kubena et al., 1989b</a>
<b>Aflatoxins</b>			
Broilers	2.5 µg/g	Decrease in red blood cell count	<a href="#">Huff et al., 1988</a>
Broilers	≥1.25 µg/g	Significant decrease in hemoglobin and erythrocyte count	<a href="#">Tung et al., 1975</a>
<b>AFB1 + OTA</b>			
Laying hens	Natural feed contamination OTA - 31 ± 3.08 µg/kg and AFB1 - 5.6 ± 0.33 µg/kg dry weight	Anemia signs (pale appearance of combs and wattles), evidenced by the discoloration of the content of the femoral medullary cavity.	<a href="#">Bozzo et al., 2023</a>

Table 1: The effects of different mycotoxins on hematological parameters – hematopoiesis

In their meta-analysis, [Andretta et al. \(2012\)](#) reported that the presence of mycotoxins in broiler diets decreased the hematocrit and the hemoglobin concentration by 5% and 15%, and aflatoxin alone decreased the parameters by 6% and 20%.

It should be evident that a simultaneous occurrence of several mycotoxins even aggravates the situation. In an experiment involving Sprague Dawley rats, administering T-2, DON, NIV, ZEA, NEO, and OTB decreased hematocrit and red blood cell counts across all mycotoxins. However, for DON, NIV, ZEN, and OTB, red blood cell values showed partial recovery after 24 hours ([Chattopadhyay, 2013](#)). Perhaps the organism learns to cope with the mycotoxins.

The examples show that Trichothecenes, such as T-2 toxin, DON, and others, as well as Ochratoxins and Aflatoxins, impact blood parameters such as hematocrit, hemoglobin, red blood cell count, and mean corpuscular volume. All these changes might lead to paleness of the skin and birds' feet and combs.

# Blood loss caused by bleeding or destruction of erythrocytes

The second possibility for anemia is blood loss due to injuries or lesions. In addition to directly causing hemorrhages, mycotoxins can promote secondary infections such as coccidiosis, which damages the gut and may produce bloody feces.

[Parent-Massin \(2004\)](#) e.g. reports on rapidly progressing coagulation problems after the ingestion of trichothecenes leading to septicemia and massive hemorrhages. Table 2 shows more examples of mycotoxins causing paleness due to blood loss.

Animal species	Dosage	Impact	Reference
<b>T-2 Toxin and other Trichothecenes</b>			
Cats	T-2 toxin – 0.06-0.1 mg/kg body weight/day	Bloody feces, hemorrhages	<a href="#">Lutsky et al., 1978</a>
Cats	T-2 toxin – 0.08 mg/kg BW every 48 h until death	Bloody feces	<a href="#">Lutzky and Mor, 1981</a>
Pigeon	DAS in oat, sifting	Emesis and bloody stools	Szathmary (1983)
Calves	0.08, 0.16, 0.32, or 0.6 mg/kg BW per day for 30 days; 1 calf per treatment	Bloody feces at doses $\geq 0.32$ mg/kg BW per day	<a href="#">Pier et al., 1976</a>
<b>Ochratoxin</b>			
Rats	Single dosages of 0, 17, or 22 mg/kg BW in 0.1 Mol/L NaHCO <sub>3</sub> , gavage	Multifocal hemorrhages in many organs	<a href="#">Albassam et al., 1987</a>
<b>DON</b>			
Broilers	0, 35, 70, 140, 280, 560, and 1120 mg/kg body weight	Ecchymotic hemorrhages throughout the intestinal tract, liver, and musculature; relationship to hemorrhagic anemia syndrome seems warranted	<a href="#">Huff et al., 1981</a>
<b>Sterigmatocystin (ST)</b>			
10-12-day old chicks (93-101 g)	10 and 14 mg/kg BW intraperitoneal	Hemorrhages and foci of necrosis in the liver	<a href="#">Sreemannarayana et al., 1987</a>
<b>Aflatoxins</b>			
Broiler chickens	100 µg/kg feed	Hemorrhages in the liver	<a href="#">Abdel-Sattar, 2019</a>
Turkeys	500 and 1000 ppb in the diet	Bloody diarrhea, spleens with hemorrhages, petechial hemorrhages in the small intestine	<a href="#">Giambrone et al., 1984</a>
Broilers	0, 0.625, 1.25, 2.5, 5.0, and 10.0 mg/kg of diet combined with Infectious Bursal Disease	Slight hemorrhages in the skeletal muscles; decreased hematocrit and hemoglobin due to hemolytic anemia.	<a href="#">Chang and Hamilton, 1981</a>

Broilers	0, 1, and 2 mg AFB1/kg of diet	Downregulation of the genes involved in blood coagulation (coagulation factor IX and X) and upregulation of anticoagulant protein C precursor, an inactivator of coagulation factors Va and VIIIa, and antithrombin-III precursor with 2 mg/kg	<a href="#">Yarru, 2009</a>
Pigs	1-4 mg/kg, 4 weeks 0.4-0.8 mg/kg, 10 weeks	Hemorrhages	<a href="#">Henry et al., 2001</a>

Table 2: The effects of different mycotoxins on hematological parameters – blood loss

## Poor pigmentation

The fourth reason for paleness can be inadequate pigmentation. According to [Hy Line \(2021\)](#), the so-called pale bird syndrome is characterized by poor skin and egg yolk pigmentation and is caused by reduced absorption of fat and carotenoid pigments in compromised birds. This is also the case when the diets contain pigment supplements. [Tyczkowski and Hamilton \(1986\)](#) observed in their experiment with chickens exposed to doses of 1-8 µg of Aflatoxins/g of diet for three weeks that aflatoxins can cause poor pigmentation in chickens, probably by impairing carotenoids absorption but also transport and deposition. [Osborne et al. \(1982\)](#) asserted that carotenoids were significantly ( $P < 0.05$ ) depressed by 2 ppm ochratoxin as well as by 2.5 ppm aflatoxin in the diet.

Another possibility is oxidative stress due to the mycotoxin challenge. As pigments also serve as antioxidants, they may be expended for this purpose and are no longer available for pigmentation.

## Paleness in poultry – a reason to think about mycotoxins

Paleness can have different causes, some of which are influenced by mycotoxins. If your chickens or hens are pale, checking the feed concerning mycotoxins is always recommended. A feed analysis can give information about possible contamination (see our tool [MasterRisk](#)).

In the case of contamination, effective products binding the mycotoxins and mitigating the adverse effects of these harmful substances can help protect your birds. As paleness is usually not the only effect of mycotoxins but also a decrease in growth, toxin binders can help maintain the performance of your animals.

### References:

- Abdel-Sattar, Ward Masoud, Kadry Mohamed Sadek, Ahmed Ragab Elbestawy, and Disouky Mohamed Mourad. "The Protective Role of Date Palm (Phoenix Dactylifera Seeds) against Aflatoxicosis in Broiler Chickens Regarding Carcass Characteristics, Hepatic and Renal Biochemical Function Tests and Histopathology." *Journal of World's Poultry Research* 9, no. 2 (June 25, 2019): 59-69. <https://doi.org/10.36380/scil.2019.wvj9>.
- Albassam, M. A., S. I. Yong, R. Bhatnagar, A. K. Sharma, and M. G. Prior. "Histopathologic and Electron Microscopic Studies on the Acute Toxicity of Ochratoxin A in Rats." *Veterinary Pathology* 24, no. 5 (September 1987): 427-35. <https://doi.org/10.1177/030098588702400510>.
- Andretta, I., M. Kipper, C.R. Lehnem, and P.A. Lovatto. "Meta-Analysis of the Relationship of Mycotoxins with Biochemical and Hematological Parameters in Broilers." *Poultry Science* 91, no. 2 (February 2012): 376-82. <https://doi.org/10.3382/ps.2011-01813>.
- Bhat, RameshV, Y Ramakrishna, SashidharR Beedu, and K.L Munshi. "Outbreak of Trichothecene Mycotoxicosis Associated with Consumption of Mould-Damaged Wheat Products in Kashmir Valley, India." *The Lancet* 333, no. 8628 (January 1989): 35-37. [https://doi.org/10.1016/s0140-6736\(89\)91684-x](https://doi.org/10.1016/s0140-6736(89)91684-x).

Bozzo, Giancarlo, Nicola Pugliese, Rossella Samarelli, Antonella Schiavone, Michela Maria Dimuccio, Elena Circella, Elisabetta Bonerba, Edmondo Ceci, and Antonio Camarda. "Ochratoxin A and Aflatoxin B1 Detection in Laying Hens for Omega 3-Enriched Eggs Production." *Agriculture* 13, no. 1 (January 5, 2023): 138. <https://doi.org/10.3390/agriculture13010138>.

Chang, Chao-Fu, and Pat B. Hamilton. "Increased Severity and New Symptoms of Infectious Bursal Disease during Aflatoxicosis in Broiler Chickens." *Poultry Science* 61, no. 6 (June 1982): 1061-68. <https://doi.org/10.3382/ps.0611061>.

Chattopadhyay, Pronobesh, Amit Agnihotri, Danswerang Ghoyary, Aadesh Upadhyay, Sanjeev Karmakar, and Vijay Veer. "Comparative Hematotoxicity of Fusarium Mycotoxin in Experimental Sprague-Dawley Rats." *Toxicology International* 20, no. 1 (2013): 25. <https://doi.org/10.4103/0971-6580.111552>.

European Commission. "Opinion of the Scientific Committee on Food on Fusarium Toxins Part 5: T-2 Toxin and HT-2 Toxin." Food.ec.europa. Accessed May 30, 2001. [https://food.ec.europa.eu/document/download/a859c348-a38e-404c-a2af-c3e29a3a8777\\_en?filename=sci-com\\_scf\\_out88\\_en.pdf](https://food.ec.europa.eu/document/download/a859c348-a38e-404c-a2af-c3e29a3a8777_en?filename=sci-com_scf_out88_en.pdf).

Giambrone, J.J., U.L. Diener, N.D. Davis, V.S. Panangala, and F.J. Hoerr. "Effect of Purified Aflatoxin on Turkeys." *Poultry Science* 64, no. 5 (May 1985): 859-65. <https://doi.org/10.3382/ps.0640859>.

Gu, Wang, Qiang Bao, Kaiqi Weng, Jinlu Liu, Shuwen Luo, Jianzhou Chen, Zheng Li, et al. "Effects of T-2 Toxin on Growth Performance, Feather Quality, Tibia Development and Blood Parameters in Yangzhou Goslings." *Poultry Science* 102, no. 2 (February 2023): 102382. <https://doi.org/10.1016/j.psj.2022.102382>.

Henry, H., T. Whitaker, I. Rabban, J. Bowers, D. Park, W. Price, F.X. Bosch, et al. "Aflatoxin M1." Aflatoxin M1 (JECFA 47, 2001). Accessed July 29, 2024. <https://inchem.org/documents/jecfa/jecmono/v47je02.htm>.

Hoerr, F., W. Carlton, B. Yagen, and A. Joffe. "Mycotoxosis Caused by Either T-2 Toxin or Diacetoxyscirpenol in the Diet of Broiler Chickens." *Fundamental and Applied Toxicology* 2, no. 3 (May 1982): 121-24. [https://doi.org/10.1016/s0272-0590\(82\)80092-4](https://doi.org/10.1016/s0272-0590(82)80092-4).

Huff, W.E., J.A. Doerr, P.B. Hamilton, and R.F. Vesonder. "Acute Toxicity of Vomitoxin (Deoxynivalenol) in Broiler Chickens," *Poultry Science* 60, no. 7 (July 1981): 1412-14. <https://doi.org/10.3382/ps.0601412>.

Huff, W.E., R.B. Harvey, L.F. Kubena, and G.E. Rottinghaus. "Toxic Synergism between Aflatoxin and T-2 Toxin in Broiler Chickens." *Poultry Science* 67, no. 10 (October 1988): 1418-23. <https://doi.org/10.3382/ps.0671418>.

Hy-Line. "Mycotoxins: How to deal with the threat of mycotoxicosis." Hy-Line International. Accessed July 29, 2024. <https://www.hyline.com/>.

Klein, P. J., T. R. Vleet, J. O. Hall, and R. A. Coulombe. "Dietary Butylated Hydroxytoluene Protects against Aflatoxicosis in Turkey." *Poisonous plants and related toxins*, November 24, 2003, 478-83. <https://doi.org/10.1079/9780851996141.0478>.

Kubena, L.F., R.B. Harvey, T.S. Edrington, and G.E. Rottinghaus. "Influence of Ochratoxin A and Diacetoxyscirpenol Singly and in Combination on Broiler Chickens." *Poultry Science* 73, no. 3 (March 1994): 408-15. <https://doi.org/10.3382/ps.0730408>.

Kubena, L.F., R.B. Harvey, W.E. Huff, D.E. Corrier, T.D. Philipps, and G.E. Rottinghaus. "Influence of Ochratoxin A and T-2 Toxin Singly and in Combination on Broiler Chickens." *Poultry Science* 68, no. 7 (July 1989): 867-72. <https://doi.org/10.3382/ps.0680867>.

Kubena, L.F., R.B. Harvey, W.E. Huff, D.E. Corrier, T.D. Phillips, and G.E. Rottinghaus. "Influence of Ochratoxin A and T-2 Toxin Singly and in Combination on Broiler Chickens." *Poultry Science* 68, no. 7 (July 1989): 867-72. <https://doi.org/10.3382/ps.0680867>.

Kubena, L.F., W.E. Huff, R.B. Harvey, T.D. Phillips, and G.E. Rottinghaus. "Individual and Combined Toxicity of Deoxynivalenol and T-2 Toxin in Broiler Chicks." *Poultry Science* 68, no. 5 (May 1989): 622-26. <https://doi.org/10.3382/ps.0680622>.

Lutsky, I.I., and N. Mor. "Alimentary Toxic Aleukia (Septic Angina, Endemic Panmyelotoxicosis, Alimentary Hemorrhagic Aleukia): T-2 Toxin-Induced Intoxication of Cats." *The American journal of pathology*, 1980. <https://pubmed.ncbi.nlm.nih.gov/6973281/>.



Lutsky, Irving, Natan Mor, Boris Yagen, and Avraham Z. Joffe. "The Role of T-2 Toxin in Experimental Alimentary Toxic Aleukia: A Toxicity Study in Cats." *Toxicology and Applied Pharmacology* 43, no. 1 (January 1978): 111-24. [https://doi.org/10.1016/s0041-008x\(78\)80036-2](https://doi.org/10.1016/s0041-008x(78)80036-2).

MEJ, Pronk, Schothorst RC, and H.P. van Egmond. "Toxicology and Occurrence of Nivalenol, Fusarenon X, Diacetoxyscirpenol, Neosolaniol and 3- and 15- Acetyldeoxynivalenol; a Review of Six Trichothecenes." Home - Web-based Archive of RIVM Publications, November 7, 2002. <https://rivm.openrepository.com/handle/10029/9184>.

Modra, Helena, Jana Blahova, Petr Marsalek, Tomas Banoch, Petr Fictum, and Martin Svoboda. "The Effects of Mycotoxin Deoxynivalenol (DON) on Haematological and Biochemical Parameters and Selected Parameters of Oxidative Stress in Piglets." *Neuro Endocrinol Lett.* 34, no. Suppl 2 (2013): 84-89.

Osborne, D.J., W.E. Huff, P.B. Hamilton, and H.R. Burmeister. "Comparison of Ochratoxin, Aflatoxin, and T-2 Toxin for Their Effects on Selected Parameters Related to Digestion and Evidence for Specific Metabolism of Carotenoids in Chickens," *Poultry Science* 61, no. 8 (August 1982): 1646-52. <https://doi.org/10.3382/ps.0611646>.

Pande, Vivek, Nitin Kulkure, and A.G. Bhandarkar. "Effect of T-2 Toxin on Growth, Performance and Haematobiochemical Alterations in Broilers ." *Indian Journal of Experimental Biology* 44, no. 1 (February 2006): 86-88.

Pier , A.C., S.J. Cysewski, J.L. Richard , A.L. Baetz, and L. Mitchell. "Experimental Mycotoxicoses in Calves with Aflatoxin, Ochratoxin, Rubratoxin, and T-2 Toxin." Proceedings, annual meeting of the United States Animal Health Association, 1976. <https://pubmed.ncbi.nlm.nih.gov/1078072/>.

Resanovic, Radmila, Ksenija Nesic, Vladimir Nesic, Todor Palic, and Vesna Jacevic. "Mycotoxins in Poultry Production." *Zbornik Matice srpske za prirodne nauke*, no. 116 (2009): 7-14. <https://doi.org/10.2298/zmspn0916007r>.

Riahi, Insaf, Virginie Marquis, Anna Maria Pérez-Vendrell, Joaquim Brufau, Enric Esteve-Garcia, and Antonio J. Ramos. "Effects of Deoxynivalenol-Contaminated Diets on Metabolic and Immunological Parameters in Broiler Chickens." *Animals* 11, no. 1 (January 11, 2021): 147. <https://doi.org/10.3390/ani11010147>.

Sreemannarayana, O., A. A. Frohlich, and R. R. Marquardt. "Acute Toxicity of Sterigmatocystin to Chicks." *Mycopathologia* 97, no. 1 (January 1987): 51-59. <https://doi.org/10.1007/bf00437331>.

Stack, Jim, and Mike Carlson. "Fumonisin in Corn." DigitalCommons@University of Nebraska - Lincoln, 2003. <https://core.ac.uk/download/pdf/188054556.pdf>.

Szathmary, C.I. "Trichothecene Toxicoses and Natural Occurrence in Hungary." Essay. In *Ueno, Y: Developments in Food Science IV. Trichothecenes*, 229-50. New York: Elsevier, 1983.

Tung, Hsi-Tang, F.W. Cook, R.D. Wyatt, and P.B. Hamilton. "The Anemia Caused by Aflatoxin." *Poultry Science* 54, no. 6 (November 1975): 1962-69. <https://doi.org/10.3382/ps.0541962>.

Tyczkowski, Juliusz K., and Pat B. Hamilton. "Altered Metabolism of Carotenoids during Aflatoxicosis in Young Chickens," *Poultry Science* 66, no. 7 (July 1987): 1184-88. <https://doi.org/10.3382/ps.0661184>.

WHO. "Selected Mycotoxins : Ochratoxins, Trichothecenes, Ergot / Published under the Joint Sponsorship of the United Nations Environment Programme, the International Labour Organisation and the World Health Organization." World Health Organization, January 1, 1990. <https://apps.who.int/iris/handle/10665/39552>.

Yohannes, T., A. K. Sharma, S. D. Singh, and V. Sumi. "Experimental Haematobiochemical Alterations in Broiler Chickens Fed with T-2 Toxin and Co-Infected with IBV." *Open Journal of Veterinary Medicine* 03, no. 05 (2013): 252-58. <https://doi.org/10.4236/ojvm.2013.35040>.

---

# Mycotoxins in poultry – External signs can give a hint



## Part 3: Bone disorders and foot pad lesions

*By Dr. Inge Heinzl, Editor, and Marisabel Caballero, Global Technical Manager Poultry*

Bone health is essential for animals and humans. Besides giving structural support, allowing movement, and protecting vital organs, the bones release hormones that are crucial for mineral homeostasis and acid balance and serve as reservoirs of energy and minerals ([Guntur & Rosen, 2012](#); [Rath, N.C. & Durairaj, 2022](#); [Suchacki et al., 2017](#)).

Bone disorders and foot pad lesions are considerable challenges in poultry production, especially for fast-growing birds with high final weights. Due to pain, the animals do not move, and dominant, healthy birds may restrict lame birds' access to feed and water. In consequence, these birds are often culled. Moreover, processing these birds is problematic, and often, they must be discarded or downgraded.

Foot pad lesions, another common issue in poultry production, can also have significant economic implications. On the one hand, pain restricts birds from eating and drinking and reduces weight gain. On the other hand, for many producers, chicken feet constitute a substantial part of the economic value of the bird; therefore, discarding them represents a significant financial loss. Additionally, to push poultry production in the right direction concerning animal health and welfare, a foot pad scoring system at the processing plant is in place in European countries.



# Mycotoxins affect bones in different ways

Mycotoxins, depending on their target organs, can have diverse effects on the skeleton of birds. For example, mycotoxins that target the liver can disrupt calcium metabolism, which in turn affects the mineralization of the bones (rickets) and the impairment of chondrocytes can slow down bone growth (e.g., tibial dyschondroplasia). When the kidneys are impacted, urate clearance decreases, plasma uric acid consequently increases, and urate crystals form in the synovial fluid and tendon sheaths of various joints, particularly the hock joints. These examples highlight the complex and varied ways mycotoxins can impact poultry bone health.

## Inadequate bone mineralization and strength - Rickets and layer cage fatigue

Sufficient bone mineralization is essential for the stability of the skeleton. Calcium (Ca), Vitamin D, and Phosphorous (P) deficiency leads to inadequate mineralization, weakens the bone, and can cause soft and bent bones or, in the case of layers, cage fatigue - a collapse of the spinal bone- and paralysis. Inadequate bone mineralization can be caused in different ways, among them:

1. Decrease in the availability of the nutrients necessary for mineralization. This can occur if the digestibility of these nutrients deteriorates
2. Impact on the Ca/P ratio—A ratio of 1 - 2:1 is vital for adequate bone development (Loughrill et al., 2016). Mycotoxins can alter absorption and transporters for one or both elements, altering their ratio.
3. Impact on the Vitamin D receptor, affecting its expression or the transporters for Ca and P.

Aflatoxins can impair bone mineralization by different modes of action. An important one is the impairment of the digestibility of Ca and P: [Kermanshahi et al. \(2007\)](#) fed broilers diets with high levels of aflatoxins (0.8 to 1.2 mg AFB1/kg feed) for three weeks, which resulted in a significant reduction of Ca and P digestibility. Other researchers, however, did not find an effect on Ca and P digestibility with lower aflatoxin levels: [Bai et al. \(2014\)](#) feeding diets contaminated with 96 (starter) and 157 µg Aflatoxins (grower) per kg of feed to broilers and [Han et al. \(2008\)](#) saw no impact on cherry valley ducks with levels of 20 and 40 µg AFB1/kg diet.

Indirectly, a decrease in the availability of Ca and P due to aflatoxin-contaminated feed can be shown by blood or tibia levels of these minerals, as demonstrated by [Zhao et al. \(2010\)](#): They conducted a trial with broilers, resulting in blood serum levels of Ca and P levels significantly ( $P < 0.05$ ) dropped with feed contaminated with 2 mg/kg of AFB1. Another trial conducted by [Bai et al. \(2014\)](#) showed decreased Ca in the tibia and reduced tibial break strength.

To get more information about the effect of mycotoxins on bone mineralization and the utilization of Ca, P, and Vit. D in animal organisms, [Costanzo et al. \(2015\)](#) challenged osteosarcoma cells with 5 and 50 ppb of aflatoxin B1. They asserted a significant down-modulation of the expression of the Vitamin D receptor. Furthermore, they assumed an interference of AFB1 with the actions of vitamin D on calcium-binding gene expression in the kidney and intestine. [Paneru et al. \(2024\)](#) could confirm this downregulation of the Vit D receptor and additionally of the Ca and P transporters in broilers with levels of  $\geq 75$  ppb AFB1. They also saw a significant reduction in tibial bone ash content at AFB1 levels  $> 230$  ppb, a decreased trabecular bone mineral content and density at AFB1 520 ppb, and a reduced bone volume and tissue volume of the cortical bone of the femur at the level of 230 ppb (see Figure 1). They concluded that AFB1 levels of already 230 ppb contribute to bone health issues in broilers.

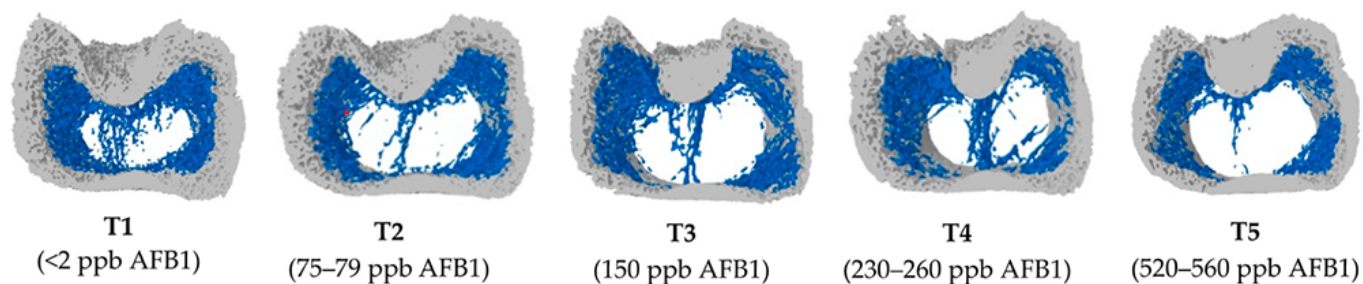


Figure 1: Increasing doses of AFB1 (<2 ppb – 560 ppb) deteriorate bone quality (Paneru, 2024): Cross-sectional images of femoral metaphysis with increasing AFB1 levels (left to right). The outer cortical bone is shown in light grey, and the inner trabecular bone in blue. Higher levels of AFB1 (T4 and T5) show a disruption of the trabecular bone pattern (less dense blue pattern with thinner and more fragmented bone strands and with wide spaces between the trabecular bone) (shown in white).

All experiments strongly suggest that aflatoxins harm bone homeostasis. Additional liver damage, oxidative stress, and impaired cellular processes can exacerbate bone health issues.

Trichothecenes also negatively impact bone mineralization. Depending on the mycotoxin, they may affect the gut, decreasing the absorption of Ca and P and probably provoking an imbalance in the Ca/P ratio.

For instance, when **T-2 toxin** was fed to Yangzhou goslings at 0.4, 0.6, and 0.8 mg/kg of diet, it decreased the Ca levels (halved at 0.8 mg/kg) and increased the P levels in the blood serum, so the Ca/P ratio decreased from the adequate ratio of 1 – 2 to 0.85, 0.66, and 0.59 ( $P < 0.05$ ) (Gu et al., 2023). The alterations of the Ca and P levels, the resulting decreasing Ca/P ratio, and an additional increase in alkaline phosphatase (ALP) suggest that T-2 toxin negatively impacts Ca absorption, increases ALP, and, therefore, disturbs calcification and bone development.

Other studies show that serum P levels decreased in broilers fed DON-contaminated feed with levels of only 2.5 mg/kg (Keçi et al., 2019). One reason for the lower P level is probably the lower dry matter intake, affecting Ca and P intake. Ca serum level is not typically reduced, which can be explained by the fact that Ca plays many critical physiological roles (e.g., nerve communication, blood coagulation, hormonal regulation), so the body keeps the blood levels by reducing bone mineralization. Another explanation is delivered by Li et al. (2020): After their trial with broilers, they stated that dietary P deficiency is more critical for bone development than Ca deficiency or Ca & P deficiency. The results of the trial conducted by Keçi et al. with DON (see above) were reduced bone mineralization, affected bone density, ash content, and ash density in the femur and tibiotarsus with a stronger impact on the tibiotarsus than on the femur.

In line with trichothecenes effects in Ca and P absorption, Ledoux et al. (1992) suppose that diarrhea caused by intake of fumonisins leads to malabsorption or maldigestion of vitamin D, calcium and phosphorus, having birds with rickets as a secondary effect.

Ochratoxin A (OTA) impairs kidney function, negatively affects vitamin D metabolism, reduces Ca absorption, and contributes to deteriorated bone strength (Devegowda and Ravikiran, 2009). Indications from Huff et al. (1980) show decreased tibia strength after feeding chickens OTA levels of 2, 4, and 8  $\mu\text{g/g}$ , and Duff et al. (1987) report similar results also in turkey poults.

A further mycotoxin possibly contributing to leg weakness is cyclopiazonic acid produced by *Aspergillus* and *Penicillium*. This mycotoxin is known for leading to eggs with thin or visibly racked shells, indicating an impairment of calcium metabolism (Devegowda and Ravikiran, 2009). Tran et al. (2023) also showed this fact with multiple mycotoxins.

The co-occurrence of different mycotoxins in the feed – the standard in praxis – increases the risk of leg issues. A trial with broiler chickens conducted by Raju and Devegowda (2000) showed a bone ash-decreasing effect of AFB1 (300  $\mu\text{g/kg}$ ), OTA (2 mg/kg), and T-2 toxin (3 mg/kg), fed individually but an incomparable higher effect when fed in combination.

## Impairment of bone growth – tibial

## dyschondroplasia (TD)

In TD, the development of long bones is impaired, and abnormal cartilage development occurs. It is frequent in broilers, with a higher incidence in males than females. It happens when the bone grows, as the soft cartilage tissue is not adequately replaced by hard bone tissue. Some mycotoxins have been related to this condition: According to [Sokolović et al. \(2008\)](#), actively dividing cells such as bone marrow are susceptible to T-2 toxin, including the tibial growth plates, which regulate chondrocyte formation, maturation, and turnover.

T-2 toxin: In a study with primary cultures of chicken tibial growth plate chondrocytes (GPCs) and three different concentrations of T-2 toxin (5, 50, and 500 nM), [He et al. \(2011\)](#) found that T-2 toxin decreased cell viability, alkaline phosphatase activity, and glutathione content ( $P < 0.05$ ). Additionally, it increased the level of reactive oxygen species and malondialdehyde in a dose-dependent way, which could be partly recompensated by adding an antioxidant (N-acetyl-cysteine). They concluded that T-2 toxin inhibits the proliferation and differentiation of GPCs and contributes, therefore, to the development of TD, altering cellular homeostasis. Antioxidants may help to reduce these effects.

[Gu et al. \(2023\)](#) investigated the closely bodyweight-related shank length and the tibia development in Yangzhou goslings fed feed with six different levels (0 to 2.0 mg/kg) of T-2 toxin for 21 days. They determined a clear dose-dependent slowed tibial length and weight growth ( $p < 0.05$ ), as well as abnormal morphological structures in the tibial growth plate. As tibial growth and shank length are closely related to weight gain ([Gu et al., 2023](#); [Gao et al., 2010](#); [Ukwu et al., 2014](#); [Yu et al., 2022](#)), their slowdown indicates lower growth performance.

Fumonisin B1 is also a potential cause of this kind of leg issue. Feeding 100 and 200 mg/kg to day-old turkey poults for 21 days led to the development of TD ([Weibking et al., 1993](#)). Possible explanations are the reduced viability of chondrocytes, as found by [Chu et al. \(1995\)](#) after 48 h of exposure, or the toxicity of FB1 to splenocytes and chondrocytes, which was shown in different primary cell cultures from chicken ([Wu et al., 1995](#)).

## Bacterial chondronecrosis with osteomyelitis lameness (BCO) can be triggered by DON and FUM

BCO presents a highly critical health and welfare issue in broiler production worldwide, and it is estimated that 1-2 % of condemnations in birds at the marketing age result from this disease. What is the reason? Today's fast-growing broilers are susceptible to stress. This enables pathogenic bacteria to compromise epithelial barriers, translocate from the gastrointestinal tract or the pulmonary system into the bloodstream, and colonize osteochondrotic microfractures in the growth plate of the long bone. This can lead to bone necrosis and subsequent lameness.

In their experiment with DON and FUM in broilers, [Alharbi et al. \(2024\)](#) showed that these mycotoxins reduce the gut's barrier strength and trigger immunosuppressive effects. They used contaminations of 0.76, 1.04, 0.94, and 0.93 mg DON/kg of feed and 2.40, 3.40, 3.20, and 3.50 mg FUM/kg diet in the starter, grower, finisher, and withdrawal phases, respectively. The team observed lameness on day 35; the mycotoxin groups always showed a significantly ( $P < 0.05$ ) higher incidence of cumulative lameness.

## The increase in uric acid leads to gout

In general, mycotoxins, which damage the kidneys and, therefore, impact the renal excretion of uric acid, are potentially a factor for gout appearance.

One of these mycotoxins is T-2 toxin. With the trial mentioned before (Yangzhou goslings, 21 days of exposure), [Gu et al. \(2023\)](#) showed that the highest dosage of the toxin (2.0 mg/kg) significantly increased uric acid in the blood ( $P < 0.05$ ), possibly leading to the deposit of uric acid crystals in the joints and to gout.

[Huff et al. \(1975\)](#) applied Ochratoxin to chicks at 0, 0.5, 1.0, 2.0, 4.0, and 8.0 µg/g of feed during the first three weeks of life. They found ochratoxin A as a severe nephrotoxin in young broilers as it caused damage to the kidneys with doses of 1.0 µg/g and higher. At 4.0 and 8.0 µg/g doses, uric acid increased by 38 and 48%, respectively (see Figure 2). [Page et al. \(1980\)](#) also reported increased uric acid after feeding 0.5 or 1.0 mg/kg of Ochratoxin A to adult white Leghorn chickens.

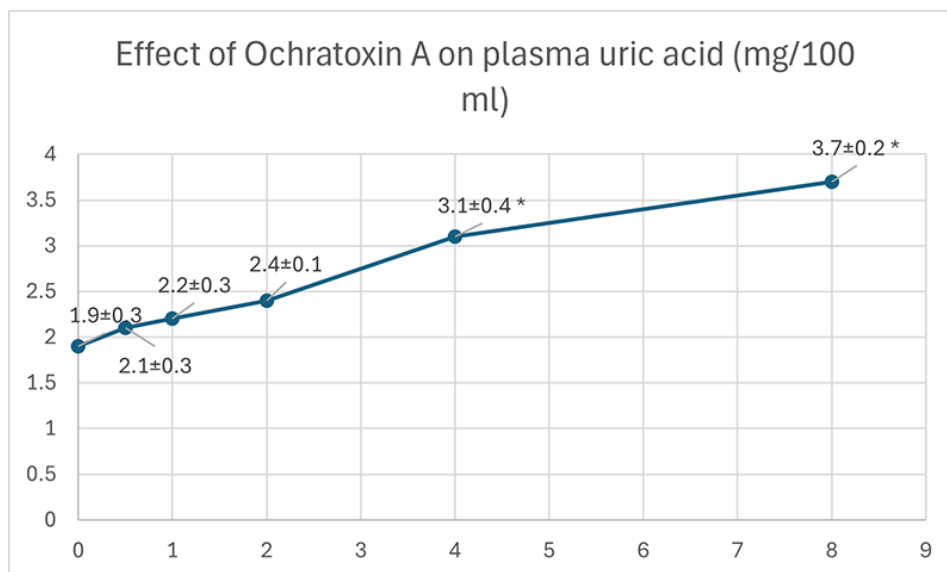


Figure 2: Effect of Ochratoxin A on plasma uric acid (mg/100 ml) (according to Huff et al., 1975)

## Foot pad lesions - a further hint of mycotoxicosis

Foot pad lesions often result from wet litter, originating from diarrhea due to harmed gut integrity. Frequently, mycotoxins impact the intestinal tract and create ideal conditions for the proliferation of diarrhea-causing microorganisms and, therefore, secondary infections. Some also negatively impact the immune defense system, allowing pathogens to settle down or aggravate existing bacterial or viral parasitic diseases. In general, mycotoxins affect the physical (intestinal cell proliferation, cell viability, cell apoptosis), chemical (mucins, AMPs), immunological, and microbial barriers of the gut, as reported by [Gao et al. \(2020\)](#). Here are some examples of the adverse effects of mycotoxins leading to intestinal disorders and diarrhea:

- Mycotoxins can modulate intestinal epithelial integrity and the renewal and repair of epithelial cells, negatively impacting the intestinal barrier's intrinsic components; for instance, DON can significantly reduce the transepithelial electrical resistance (TEER) ([Grenier and Applegate, 2013](#)). A higher permeability of the epithelium and a decreased absorption of dietary proteins can lead to higher protein in the digesta in the small intestine, which serves as a nutrient for pathogens including *perfringens* ([Antonissen et al., 2014](#); [Antonissen et al., 2015](#)).
- The application of Ochratoxin A (3 mg/kg) increased the number of *S. typhimurium* in the duodenum and ceca of White Leghorn chickens (Fukata et al., 1996). Another trial with broiler chicks at a concentration of 2 mg/kg aggravated the symptoms due to an infection by *S. gallinarum* (Gupta et al., 2005).
- In a trial by Grenier et al., 2016, feed contaminated with DON (1.5 mg/kg), Fumonisin B (20 mg/kg), or both mycotoxins aggravated lesions caused by coccidia.
- DON impacts the mucus layer composition by downregulating the expression of the gene coding for MUC2, as shown in a trial with human goblet cells (Pinton et al., 2015). The mucus layer prevents pathogenic bacteria in the intestinal lumen from contacting the intestinal epithelium ([McGuckin et al., 2011](#)).
- Furthermore, DON and other mycotoxins decrease the populations of lactic acid-producing bacteria, indicating a shift in the microbial balance ([Antonissen et al., 2016](#)).
- FB1 causes intestinal disturbances such as diarrhea, although it is poorly absorbed in the intestine. According to [Bouhet and Oswald \(2007\)](#), the main toxicological effect ascertained in



vivo and in vitro is the accumulation of sphingoid bases associated with the depletion of complex sphingolipids. This negative impact on the sphingolipid biosynthesis pathway could explain other adverse effects, such as reduced intestinal epithelial cell viability and proliferation, modification of cytokine production, and impairment of intestinal physical barrier function.

- T-2 toxin can disrupt the immune response, enhance the proliferation of *coli* in the gut, and increase its efflux ([Zhang et al., 2022](#)).

All these mycotoxins can cause foot pad lesions by impacting gut integrity or damaging the gut mucosa. They promote pathogenic organisms and, thus, provoke diarrhea and wet litter.

## Mitigating the negative impact of mycotoxins on bones and feet is crucial for performance

Healthy bones and feet are essential for animal welfare and performance. Mycotoxins can be obstructive. Consequently, the first step to protecting your animals is to monitor their feed. If the analyses show the occurrence of mycotoxins at risky levels, proactive measures must be taken to mitigate the issues and ensure the health and productivity of your poultry.

### References

Alharbi, Khawla, Nnamdi Ekesi, Amer Hasan, Andi Asnayanti, Jundi Liu, Raj Murugesan, Shelby Ramirez, Samuel Rochell, Michael T. Kidd, and Adnan Alrubaye. "Deoxynivalenol and Fumonisin Predispose Broilers to Bacterial Chondronecrosis with Osteomyelitis Lameness." *Poultry Science* 103, no. 5 (May 2024): 103598. <https://doi.org/10.1016/j.psj.2024.103598>.

Antonissen, Gunther, Filip Van Immerseel, Frank Pasmans, Richard Ducatelle, Freddy Haesebrouck, Leen Timbermont, Marc Verlinden, et al. "The Mycotoxin Deoxynivalenol Predisposes for the Development of Clostridium Perfringens-Induced Necrotic Enteritis in Broiler Chickens." *PLoS ONE* 9, no. 9 (September 30, 2014). <https://doi.org/10.1371/journal.pone.0108775>.

Antonissen, Gunther, Filip Van Immerseel, Frank Pasmans, Richard Ducatelle, Geert P. Janssens, Siegrid De Baere, Konstantinos C. Mountzouris, et al. "Mycotoxins Deoxynivalenol and Fumonisin Alter the Extrinsic Component of Intestinal Barrier in Broiler Chickens." *Journal of Agricultural and Food Chemistry* 63, no. 50 (December 10, 2015): 10846–55. <https://doi.org/10.1021/acs.jafc.5b04119>.

Antonissen, Gunther, Venessa Eeckhaut, Karolien Van Driessche, Lonneke Onrust, Freddy Haesebrouck, Richard Ducatelle, Robert J Moore, and Filip Van Immerseel. "Microbial Shifts Associated with Necrotic Enteritis." *Avian Pathology* 45, no. 3 (May 3, 2016): 308–12. <https://doi.org/10.1080/03079457.2016.1152625>.

Bai, Shiping, Leilei Wang, Yuheng Luo, Xumei Ding, Jun Yang, Jie Bai, Keying Zhang, and Jianping Wang. "Effects of Corn Naturally Contaminated with Aflatoxins on Performance, Calcium and Phosphorus Metabolism, and Bone Mineralization of Broiler Chicks." *The Journal of Poultry Science* 51, no. 2 (2014): 157–64. <https://doi.org/10.2141/jpsa.0130053>.

Bouhet, Sandrine, and Isabelle P. Oswald. "The Intestine as a Possible Target for Fumonisin Toxicity." *Molecular Nutrition & Food Research* 51, no. 8 (August 2007): 925–31. <https://doi.org/10.1002/mnfr.200600266>.

Chi, M.S., C.J. Mirocha, H.J. Kurtz, G. Weaver, F. Bates, W. Shimoda, and H.R. Burmeister. "Acute Toxicity of T-2 Toxin in Broiler Chicks and Laying Hens .," *Poultry Science* 56, no. 1 (January 1977): 103–16. <https://doi.org/10.3382/ps.0560103>.

Chu, Qili, Weidong Wu, Mark E. Cook, and Eugene B. Smalley. "Induction of Tibial Dyschondroplasia and Suppression of Cell-Mediated Immunity in Chickens by Fusarium Oxysporum Grown on Sterile Corn." *Avian Diseases* 39, no. 1 (January 1995): 100. <https://doi.org/10.2307/1591988>.

Costanzo, Paola, Antonello Santini, Luigi Fattore, Ettore Novellino, and Alberto Ritieni. "Toxicity of Aflatoxin B1 towards the Vitamin D Receptor (VDR)." *Food and Chemical Toxicology* 76 (February 2015): 77–79.

<https://doi.org/10.1016/j.fct.2014.11.025>.

Costanzo, Paola, Antonello Santini, Luigi Fattore, Ettore Novellino, and Alberto Ritieni. "Toxicity of Aflatoxin B1 towards the Vitamin D Receptor (VDR)." *Food and Chemical Toxicology* 76 (February 2015): 77–79. <https://doi.org/10.1016/j.fct.2014.11.025>.

Debouck, C., E. Haubruge, P. Bollaerts, D. van Bignoot, Y. Brostaux, A. Werry, and M. Rooze. "Skeletal Deformities Induced by the Intraperitoneal Administration of Deoxynivalenol (Vomitoxin) in Mice." *International Orthopaedics* 25, no. 3 (March 24, 2001): 194–98. <https://doi.org/10.1007/s002640100235>.

Devegowda, G., and D. Ravikiran. "Mycotoxins and Skeletal Problems in Poultry." *World Mycotoxin Journal* 2, no. 3 (August 1, 2009): 331–37. <https://doi.org/10.3920/wmj2008.1085>.

Duff, S.R.I., R.B. Burns, and P. Dwivedi. "Skeletal Changes in Broiler Chicks and Turkey Poults Fed Diets Containing Ochratoxin a." *Research in Veterinary Science* 43, no. 3 (November 1987): 301–7. [https://doi.org/10.1016/s0034-5288\(18\)30798-7](https://doi.org/10.1016/s0034-5288(18)30798-7).

Fukata, T., K. Sasai, E. Baba, and A. Arakawa. "Effect of Ochratoxin A on Salmonella Typhimurium-Challenged Layer Chickens." *Avian Diseases* 40, no. 4 (October 1996): 924. <https://doi.org/10.2307/1592318>.

Gao, Y., Z.-Q. Du, C.-G. Feng, X.-M. Deng, N. Li, Y. Da, and X.-X. Hu. "Identification of Quantitative Trait Loci for Shank Length and Growth at Different Development Stages in Chicken." *Animal Genetics* 41, no. 1 (January 6, 2010): 101–4. <https://doi.org/10.1111/j.1365-2052.2009.01962.x>.

Grenier, Bertrand, Ilse Dohnal, Revathi Shanmugasundaram, Susan Eicher, Ramesh Selvaraj, Gerd Schatzmayr, and Todd Applegate. "Susceptibility of Broiler Chickens to Coccidiosis When Fed Subclinical Doses of Deoxynivalenol and Fumonisin—Special Emphasis on the Immunological Response and the Mycotoxin Interaction." *Toxins* 8, no. 8 (July 27, 2016): 231. <https://doi.org/10.3390/toxins8080231>.

Gu, Wang, Qiang Bao, Kaiqi Weng, Jinlu Liu, Shuwen Luo, Jianzhou Chen, Zheng Li, et al. "Effects of T-2 Toxin on Growth Performance, Feather Quality, Tibia Development and Blood Parameters in Yangzhou Goslings." *Poultry Science* 102, no. 2 (February 2023): 102382. <https://doi.org/10.1016/j.psj.2022.102382>.

Guntur, Anyonya R., and Clifford J. Rosen. "Bone as an Endocrine Organ." *Endocrine Practice* 18, no. 5 (September 2012): 758–62. <https://doi.org/10.4158/ep12141.ra>.

Gupta, S., N. Jindal, R.S. Khokhar, A.K. Gupta, D.R. Ledoux, and G.E. Rottinghaus. "Effect of Ochratoxin A on Broiler Chicks Challenged with *Salmonella Gallinarum*." *British Poultry Science* 46, no. 4 (August 2005): 443–50. <https://doi.org/10.1080/00071660500190850>.

Han, Xin-Yan, Qi-Chun Huang, Wei-Fen Li, Jun-Fang Jiang, and Zi-Rong Xu. "Changes in Growth Performance, Digestive Enzyme Activities and Nutrient Digestibility of Cherry Valley Ducks in Response to Aflatoxin B1 Levels." *Livestock Science* 119, no. 1–3 (December 2008): 216–20. <https://doi.org/10.1016/j.livsci.2008.04.006>.

He, Shao-jun, Jia-fa Hou, Yu-yi Dai, Zhen-lei Zhou, and Yi-feng Deng. "N-acetyl-cysteine Protects Chicken Growth Plate Chondrocytes from T-2 Toxin-induced Oxidative Stress." *Journal of Applied Toxicology* 32, no. 12 (July 28, 2011): 980–85. <https://doi.org/10.1002/jat.1697>.

Hou, Hai-Feng, Jin-Ping Li, Guo-Yong Ding, Wen-Jing Ye, Peng Jiao, and Qun-Wei Li. "The Cytotoxic Effect and Injury Mechanism of Deoxynivalenol on Articular Chondrocytes in Human Embryo." *Zhonghua Yu Fang Yi Xue Za Zhi* 45, no. 7 (July 2011): 629–32.

Huff, W. E., R. D. Wyatt, and P. B. Hamilton. "Nephrotoxicity of Dietary Ochratoxin A in Broiler Chickens1." *Applied Microbiology* 30, no. 1 (1975): 48–51. <https://doi.org/10.1128/aem.30.1.48-51.1975>.

Huff, William E., John A. Doerr, Pat B. Hamilton, Donald D. Hamann, Robert E. Peterson, and Alex Ciegler. "Evaluation of Bone Strength during Aflatoxicosis and Ochratoxicosis." *Applied and Environmental Microbiology* 40, no. 1 (July 1980): 102–7. <https://doi.org/10.1128/aem.40.1.102-107.1980>.

Kermanshahi, H., M.R. Akbari, M. Maleki, and M. Behgar. "Effect of Prolonged Low Level Inclusion of Aflatoxin B1 into Diet on Performance, Nutrient Digestibility, Histopathology and Blood Enzymes of Broiler Chickens." *J of Anim and Vet Adv* 6, no. 5 (2007): 686–92.

Keçi, Marsel, Annegret Lucke, Peter Paulsen, Qendrim Zebeli, Josef Böhm, and Barbara U. Metzler-Zebeli.

"Deoxynivalenol in the Diet Impairs Bone Mineralization in Broiler Chickens." *Toxins* 11, no. 6 (June 18, 2019): 352. <https://doi.org/10.3390/toxins11060352>.

Ledoux, David R., Tom P. Brown, Tandice S. Weibking, and George E. Rottinghaus. "Fumonisin Toxicity in Broiler Chicks." *Journal of Veterinary Diagnostic Investigation* 4, no. 3 (July 1992): 330-33. <https://doi.org/10.1177/104063879200400317>.

Li, Tingting, Guanzhong Xing, Yuxin Shao, Liyang Zhang, Sufen Li, Lin Lu, Zongping Liu, Xiudong Liao, and Xugang Luo. "Dietary Calcium or Phosphorus Deficiency Impairs the Bone Development by Regulating Related Calcium or Phosphorus Metabolic Utilization Parameters of Broilers." *Poultry Science* 99, no. 6 (June 2020): 3207-14. <https://doi.org/10.1016/j.psj.2020.01.028>.

Loughrill, Emma, David Wray, Tatiana Christides, and Nazanin Zand. "Calcium to Phosphorus Ratio, Essential Elements and Vitamin D Content of Infant Foods in the UK: Possible Implications for Bone Health." *Maternal & Child Nutrition* 13, no. 3 (September 9, 2016). <https://doi.org/10.1111/mcn.12368>.

McGuckin, Michael A., Sara K. Lindén, Philip Sutton, and Timothy H. Florin. "Mucin Dynamics and Enteric Pathogens." *Nature Reviews Microbiology* 9, no. 4 (March 16, 2011): 265-78. <https://doi.org/10.1038/nrmicro2538>.

Morishita, Y., K. Nagasawa, Naoko Nakano, and Kimiko Shiromizu. "Bacterial Overgrowth in the Jejunum of ICR Mice and Wistar Rats Orally Administered with a Single Lethal Dose of Fusarenon-x, a Trichothecene Mycotoxin." *Journal of Applied Bacteriology* 66, no. 4 (April 1989): 263-70. <https://doi.org/10.1111/j.1365-2672.1989.tb02478.x>.

Paneru, Deependra, Milan Kumar Sharma, Hanyi Shi, Jinquan Wang, and Woo Kyun Kim. "Aflatoxin B1 Impairs Bone Mineralization in Broiler Chickens." *Toxins* 16, no. 2 (February 2, 2024): 78. <https://doi.org/10.3390/toxins16020078>.

Pegram, R.A., and R.D. Wyatt. "Avian Gout Caused by Oosporein, a Mycotoxin Produced by *Chaetomium Trilaterale*." *Poultry Science* 60, no. 11 (November 1981): 2429-40. <https://doi.org/10.3382/ps.0602429>.

Persico, Marco, Raffaele Sessa, Elena Cesaro, Irene Dini, Paola Costanzo, Alberto Ritieni, Caterina Fattorusso, and Michela Grosso. "A Multidisciplinary Approach Disclosing Unexplored Aflatoxin B1 Roles in Severe Impairment of Vitamin D Mechanisms of Action." *Cell Biology and Toxicology* 39, no. 4 (September 6, 2022): 1275-95. <https://doi.org/10.1007/s10565-022-09752-y>.

Pinton, Philippe, Fabien Graziani, Ange Pujol, Cendrine Nicoletti, Océane Paris, Pauline Ernouf, Eric Di Pasquale, Josette Perrier, Isabelle P. Oswald, and Marc Maresca. "Deoxynivalenol Inhibits the Expression by Goblet Cells of Intestinal Mucins through a PKR and MAP Kinase Dependent Repression of the Resistin-like Molecule  $\beta$ ." *Molecular Nutrition & Food Research* 59, no. 6 (April 27, 2015): 1076-87. <https://doi.org/10.1002/mnfr.201500005>.

Raju, M.V.L.N., and G. Devegowda. "Influence of Esterified-Glucomannan on Performance and Organ Morphology, Serum Biochemistry and Haematology in Broilers Exposed to Individual and Combined Mycotoxicosis (Aflatoxin, Ochratoxin and T-2 Toxin)." *British Poultry Science* 41, no. 5 (December 2000): 640-50. <https://doi.org/10.1080/713654986>.

Rath, Narayan C., and Vijay Durairaj. "Avian Bone Physiology and Poultry Bone Disorders." *Sturkie's Avian Physiology*, 2022, 549-63. <https://doi.org/10.1016/b978-0-12-819770-7.00037-2>.

Siller, W.G. "Renal Pathology of the Fowl — a Review." *Avian Pathology* 10, no. 3 (July 1981): 187-262. <https://doi.org/10.1080/03079458108418474>.

Suchacki, Karla J, Fiona Roberts, Andrea Lovdel, Colin Farquharson, Nik M Morton, Vicky E MacRae, and William P Cawthorn. "Skeletal Energy Homeostasis: A Paradigm of Endocrine Discovery." *Journal of Endocrinology* 234, no. 1 (July 2017). <https://doi.org/10.1530/joe-17-0147>.

Tran, Si-Trung, Y. Ruangpanit, K. Rassmidatta, K. Pongmanee, K. Palanisamy, and M. Caballero. "The World Mycotoxin Forum, 14th Conference." In *WMF Meets Belgium - Abstracts of Lectures and Posters*, 120-21. Antwerp: Conference Secretariat Bastiaanse Communication, 2023.

Ukwu, H.O, V.M.O. Okoro, and R.J. Nosike. "Statistical Modelling of Body Weight and Linear Body Measurements in Nigerian Indigenous Chicken." *IOSR Journal of Agriculture and Veterinary Science (IOSR-JAVS)*, Ver. V, 7, no. 1

(2014): 27-30.

Wright, G.C., Walter F.O. Marasas, and Leon Sokoloff. "Effect of Fusarochromanone and T-2 Toxin on Articular Chondrocytes in Monolayer Culture in Monolayer Culture." *Toxicological Sciences* 9, no. 3 (1987): 595-97. <https://doi.org/10.1093/toxsci/9.3.595>.

Wu, Weidong, Mark E. Cook, Qili Chu, and Eugene B. Smalley. "Tibial Dyschondroplasia of Chickens Induced by Fusarochromanone, a Mycotoxin." *Avian Diseases* 37, no. 2 (April 1993): 302. <https://doi.org/10.2307/1591653>.

Wu, Weidong, Tianxing Liu, and Ronald F. Vesonder. "Comparative Cytotoxicity of Fumonisin B1 and Moniliformin in Chicken Primary Cell Cultures." *Mycopathologia* 132, no. 2 (November 1995): 111-16. <https://doi.org/10.1007/bf01103783>.

Yu, Jun, Yu Wan, Haiming Yang, and Zhiyue Wang. "Age- and Sex-Related Changes in Body Weight, Muscle, and Tibia in Growing Chinese Domestic Geese (*Anser Domesticus*)." *Agriculture* 12, no. 4 (March 25, 2022): 463. <https://doi.org/10.3390/agriculture12040463>.

Zhang, Jie, Xuerun Liu, Ying Su, and Tushuai Li. "An Update on T2-Toxins: Metabolism, Immunotoxicity Mechanism and Human Assessment Exposure of Intestinal Microbiota." *Heliyon* 8, no. 8 (August 2022). <https://doi.org/10.1016/j.heliyon.2022.e10012>.

Zhao, J., R.B. Shirley, J.D. Dibner, F. Uraizee, M. Officer, M. Kitchell, M. Vazquez-Anon, and C.D. Knight. "Comparison of Hydrated Sodium Calcium Aluminosilicate and Yeast Cell Wall on Counteracting Aflatoxicosis in Broiler Chicks." *Poultry Science* 89, no. 10 (October 2010): 2147-56. <https://doi.org/10.3382/ps.2009-00608>.

---

## Masked mycotoxins - particularly dangerous for dairy cows





By **Si-Trung Tran**, SEAP Regional Technical Manager, EW Nutrition

**Marisabel Caballero**, Global Technical Manager Poultry, EW Nutrition, and  
**Inge Heinzl**, Editor, EW Nutrition

Mycotoxins are secondary metabolites of fungi, commonly found as contaminants in agricultural products. In some cases, these compounds are used in medicine or industry, such as penicillin and patulin. In most cases, however, they are considered xenobiotics that are toxic to animals and humans, causing the disease collectively known as mycotoxicosis. The adverse effects of mycotoxins on human and animal health have been documented in many publications. Aflatoxins (AFs) and deoxynivalenol (DON, vomitoxin) are amongst the most critical mycotoxins affecting milk production and -quality.

## Aflatoxins do not only affect cows

Aflatoxins (AFs) are highly oxygenated, heterocyclic difuranocoumarin compounds produced by *Aspergillus flavus* and *Aspergillus parasiticus*. They colonize crops, including many staple foods and feed ingredients. Within a group of over 20 AFs and derivatives, aflatoxin B1 (AFB1), B2, G1, and G2 are the most important naturally occurring compounds.

Among the aflatoxins, AFB1 is the most widespread and most toxic to humans and animals. Concern about mycotoxin contamination in dairy products began in the 1960s with the first reported cases of contamination by aflatoxin M1 (AFM1), a metabolite of AFB1 formed in the liver of animals and excreted in the milk.

There is ample evidence that lactating cows exhibit a significant reduction in feed efficiency and milk yield within a few days of consuming aflatoxin-contaminated feed. At the cellular level, aflatoxins cause degranulation of endoplasmic membranes, loss of ribosomes from the endoplasmic reticulum, loss of nuclear chromatin material, and altered nuclear shapes. The liver, as the organ mainly dealing with the decontamination of the organism, gets damaged, and performance drops. Immune cells are also affected, reducing immune competence and vaccination success ([Arnold and Gaskill, 2023](#)).

## DON reduces cows' performance

Another mycotoxin that can also reduce milk quality and affect metabolic parameters, as well as the immune function of dairy cows, is DON. DON is produced by different fungi of the *Fusarium* genus that infect plants. DON synthesis is associated with rainy weather from crop flowering to harvest. [Whitlow and co-workers](#) (1994) reported the association between DON and poor performance in dairy herds and showed decreased milk production in dairy cows fed 2.5 mg DON/kg. However, in cows fed 6 to 12 mg DON/kg dry matter for 10 weeks, no DON or its metabolite DOM-1 residues were detected in milk.

## Masked mycotoxins hide themselves during analysis

Plants suffering from fungal infestations and thus confronted with mycotoxins convert the harmful forms of mycotoxins into less harmful or harmless ones for themselves by conjugation to sulfates, organic acids, or sugars. Conjugated mycotoxins cannot always be detected by standard analytical methods. However, in animals, these forms can be released and transformed into parent compounds by enzymes and microorganisms in the gastrointestinal tract. Thus, the feed may show a concentration of mycotoxins that is still below the limit value, but in the animal, this concentration is suddenly much higher. In dairy cows, the release of free mycotoxins from conjugates during digestion may play an important role in understanding the silent effects of mycotoxins.

Fusarium toxins, in particular, frequently occur in this “masked form”. They represent a serious health risk for animals and humans.

# Aflatoxins first show up in the milk

Masked aflatoxins may also play a role in total aflatoxin contamination of feed materials. Research has harvested little information on masked aflatoxins that may be present in TMR ingredients. So far, metabolites such as Aflatoxin M2 have been identified ([Righetti, 2021](#)), which may reappear later in milk as AFM1.

## DON-related symptoms without DON?

Sometimes, animals show DON-related symptoms, with low levels detected in the feed or raw materials. Besides sampling errors, this enigma could be due to conjugated or masked DON, which is structurally altered DON bound to various compounds such as glucose, fatty acids, and amino acids. These compounds escape conventional feed analysis techniques because of their modified chemical properties but can be released as their toxic precursors after acid hydrolysis.

Masked DON was first described in 1984 by [Young and co-workers](#), who found that the DON content of yeast-fermented foods was higher than that of the contaminated wheat flour used in their production. The most plausible reason for this apparent increase was that the toxin from the wheat had been converted to a compound other than DON, which could be converted back to DON under certain conditions. Since this report, there has been much interest in conjugated or masked DON.

## Silage: masked DON is a challenge for dairy producers

Silage is an essential feed for dairy cows, supporting milk production. Most silage is made from corn and other grains. The whole green plant is used, which can be infected by fungi. Since infection of corn with *Fusarium* spp. and subsequent DON contamination is usually a major problem in the field worldwide, a relatively high occurrence of this toxin in silage must be expected. The ensiling process may reduce the amount of *Fusarium* fungi, but the DON formed before ensiling is very stable.



## Silage samples show DON levels of concern

It is reasonable to assume that the DON biosynthesized by the fungi was metabolized by the plants to a new compound and thus masked DON. Under ensiling conditions, masked DON can be hydrolyzed, producing free DON again. Therefore, the level of free DON in the silage may not reflect the concentration

measured in the plants before ensiling.

A study analyzed 50 silage samples from different farms in Ontario, Canada. Free DON was found in all samples, with levels ranging from 0.38 to 1.72 µg/g silage (unpublished data). Eighty-six percent of the samples contained DON at concentrations higher than 0.5 µg/g. Together with masked DON, it poses a potential threat to dairy cattle.

## **Specific hydrolysis conditions allow detection**

However, in the natural ensiling process, the conditions for hydrolysis of masked DON are not optimal. The conditions that allow improved analysis of masked DON were recently described. This method detected masked DON in 32 of 50 silage samples (64%) along with free DON, increasing DON concentration by 23% in some cases (unpublished data).

## **Mycotoxins impact humans and animals**

Aflatoxins, as well as DON, have adverse effects. In the case of DON, the impact on the animal is significant; in the case of aflatoxin, the possible long-term effects on humans are of higher relevance.

## **DON has more adverse effects on the animal and its performance**

Unlike AFs, DON may be found in milk at low or trace concentrations. It is more associated with negative effects in the animal, altered rumen fermentation, and reduced flow of usable protein into the duodenum. For example, milk fat content was significantly reduced when cows were fed 6 µg DON/kg. However, the presence of DON also indicates that the feed probably contains other mycotoxins, such as zearalenone (ZEA) (estrogenic mycotoxin) and fusaric acid (pharmacologically active compound). All these mycotoxins may interact to cause symptoms that are different or more severe than expected, considering their individual effects. DON and related compounds also have immunosuppressive effects, resulting in increased somatic cell counts in milk. The U.S. FDA has established an action level for DON in wheat and wheat-derived products intended for cows, which is 5µg DON/g feed and the contaminated ingredient must not exceed 40% of the ration.

## **Aflatoxins decrease milk quality and pose a risk to humans**

Aflatoxins are poorly degraded in the rumen, with aflatoxicol being the main metabolite that can be reconverted to AFB1. Most AFs are absorbed and extensively metabolized/hydrolyzed by enzymes found mainly in the liver. This results in the formation of AFM1, a part of which is conjugated to glucuronic acid and subsequently excreted in the bile. The other part enters the systemic circulation. It is either excreted in urine or milk. AFM1 appears within 12-48 hours after ingestion in cow's milk. The excreted amount of AFM1 in milk from dairy cows usually ranges from 0.17% to 3% of the ingested AFB1. However, this carryover rate may vary from day to day and from one milking to the next in individual animals, as it is influenced by various factors, such as feeding regime, health status, individual biotransformation capacity, and, of course, by actual milk production. Carryover rates of up to 6.2% have been reported in high-yielding dairy cows producing up to 40 liters of milk per day.

In various experiments, AFM1 showed both carcinogenic and immunosuppressive effects. Accordingly, the International Agency for Research on Cancer (IARC) classified AFM1 as being in Group 2B and, thus, possibly carcinogenic in humans. The action level of 0.50 ppb and 0.05 ppb for AFM1 in milk is strictly adhered to by the U.S. Food and Drug Administration (FDA) and the European Food Safety Authority (EFSA), respectively.

# Trials show the high adsorption capacity of Solis Max

A trial was conducted at an independent laboratory located in Spain. The evaluation of the performance of Solis Max was executed with the following inclusion levels:

- 0.10% equivalent to 1.0 kg of Solis Max per ton of feed
- 0.20% equivalent to 2.0 kg of Solis Max per ton of feed

A phosphate buffer solution at pH 7 was prepared for the trial to simulate rumen conditions. Each mycotoxin was tested separately, preparing solutions with known contamination (final concentration described in the table below). The contaminated solutions were divided into 3 parts: A positive control, 0.10% Solis Max and 0.20% Solis Max. All samples were incubated at 41°C for 1 hour, centrifuged, and the supernatant was analyzed for the mycotoxin added to determine the binding efficacy. All analyses were carried out by high-performance liquid chromatography (HPLC) with standard detectors.

Mycotoxin	Contamination Level (ppb)
Aflatoxin B1	800
DON	800
Fumonisin B1	2000
ZEA	1200

## Results:

The higher concentration of Solis max showed a higher adsorption rate for most mycotoxins. The high dose of Solis Max adsorbed 99% of the AFB1 contamination. In the case of DON, more than 70% was bound. For fumonisin B1 and zearalenone, Solis max showed excellent binding rates of 87.7% and 78.9%, respectively (Figure 1).

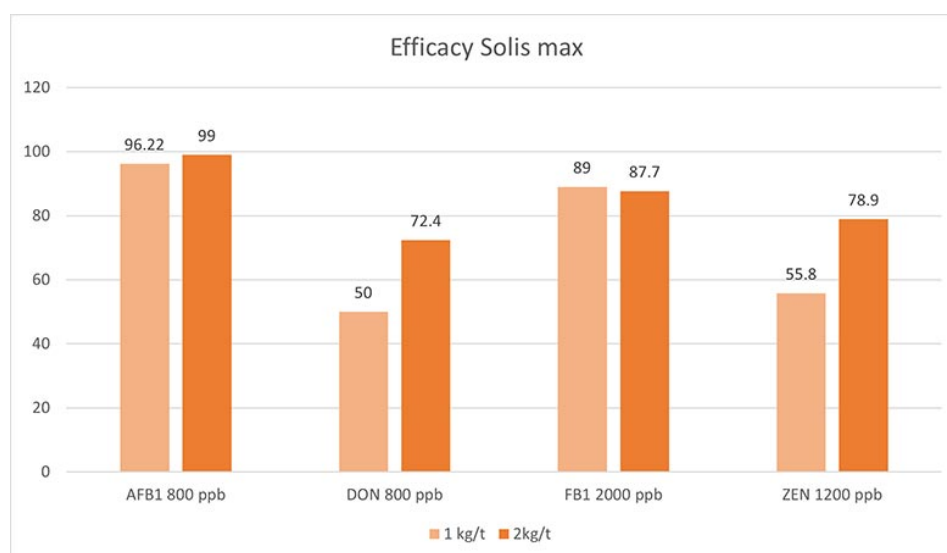


Figure 1: Solis Max showed a high binding capacity for the most relevant mycotoxins

Another trial was conducted at an independent laboratory serving the food and feed industry and located in Valladolid, Spain.

All tests were carried out as duplicates and using a standard liquid chromatography/mass spectrometry (LC/MS/MS) quantification. Interpretation and data analysis were carried out with the corresponding software. The used pH was 3.0, toxin concentrations and anti-mycotoxin agent application rates were set as follows (Table 1):

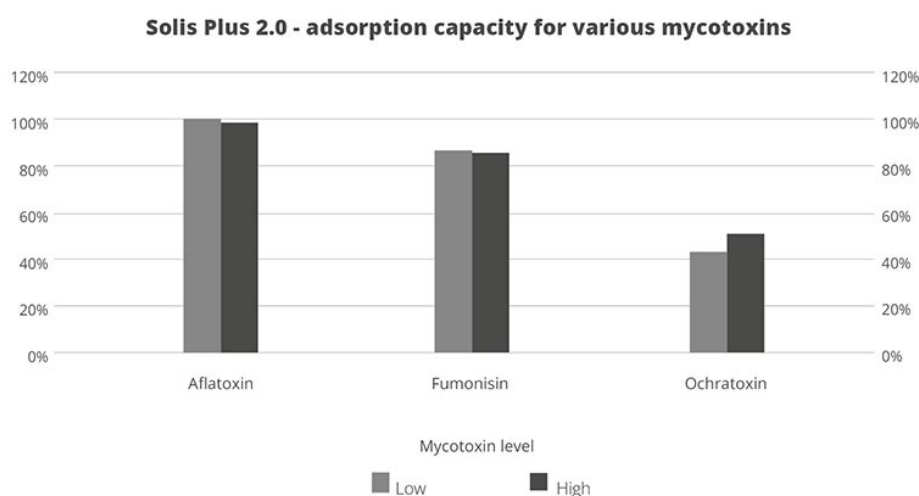


Mycotoxin	Challenge level	Challenge (ppb)	Solis Plus 2.0 inclusion	Assay time
Aflatoxin	Low	150	0.2%	30 min.
	High	1500	0.2%	30 min.
Fumonisin	Low	500	0.2%	30 min.
	High	5000	0.2%	30 min.
Ochratoxin	Low	150	0.2%	30 min.
	High	1500	0.2%	30 min.

*Table 1: Trial set-up testing the binding capacity of Solis Plus 2.0 for several mycotoxins in different contamination levels*

## Results:

Under acidic conditions (pH3), Solis Plus 2.0 effectively adsorbs the three tested mycotoxins at low and high levels. 100% binding of aflatoxin was achieved at a level of 150ppb and 98% at 1500ppb. In the case of fumonisin, 87% adsorption could be reached at 500ppb and 86 for a challenge with 5000ppb. 43% ochratoxin was adsorbed at the contamination level of 150ppb and 52% at 1500ppb.



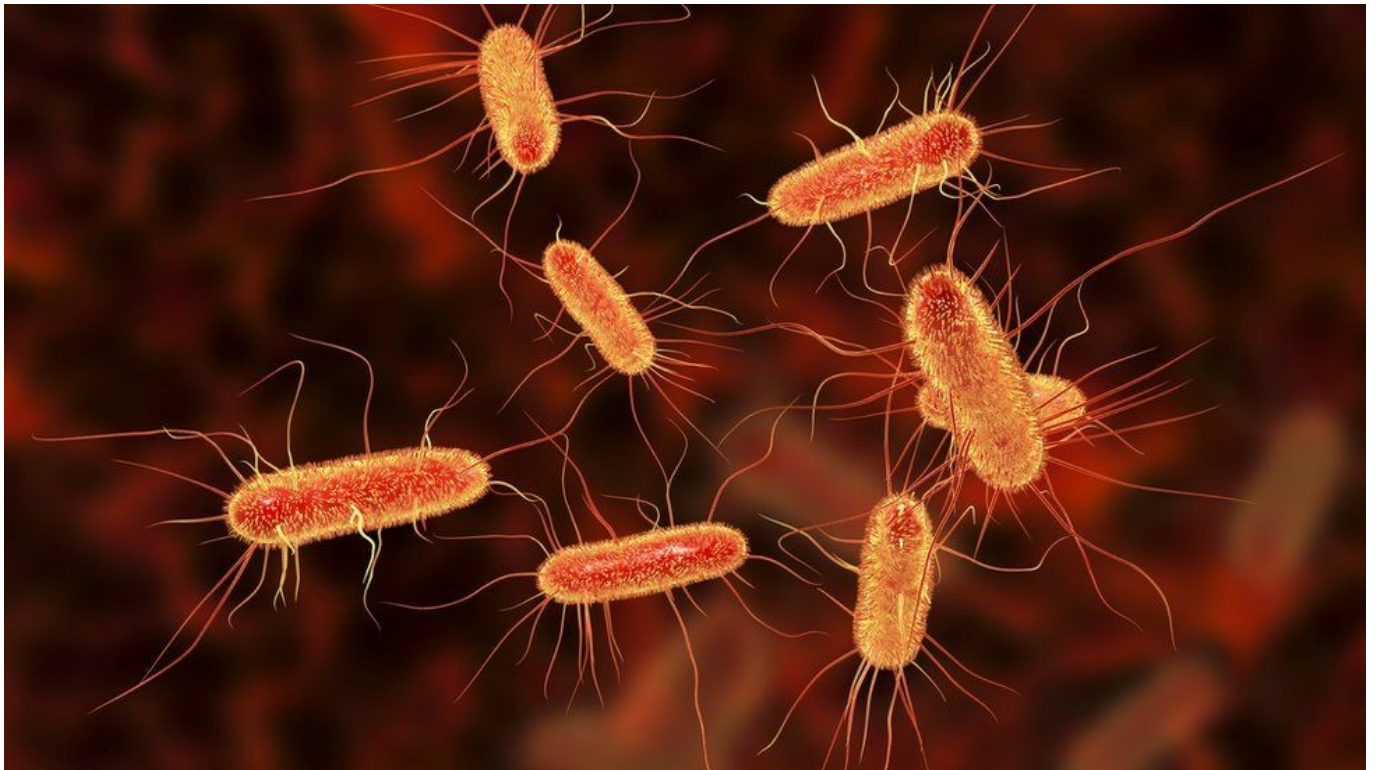
*Figure 2: The adsorption capacity of Solis Plus 2.0 for three different mycotoxins at two challenge levels*

# Mycotoxins - Effective risk management is of paramount importance

Although the rumen microflora may be responsible for conferring some mycotoxin resistance to ruminants compared to monogastric animals, there are still effects of mycotoxins on rumen fermentation and milk quality. In addition, masked mycotoxins in feed present an additional challenge for dairy farms because they are not readily detectable by standard analyses.

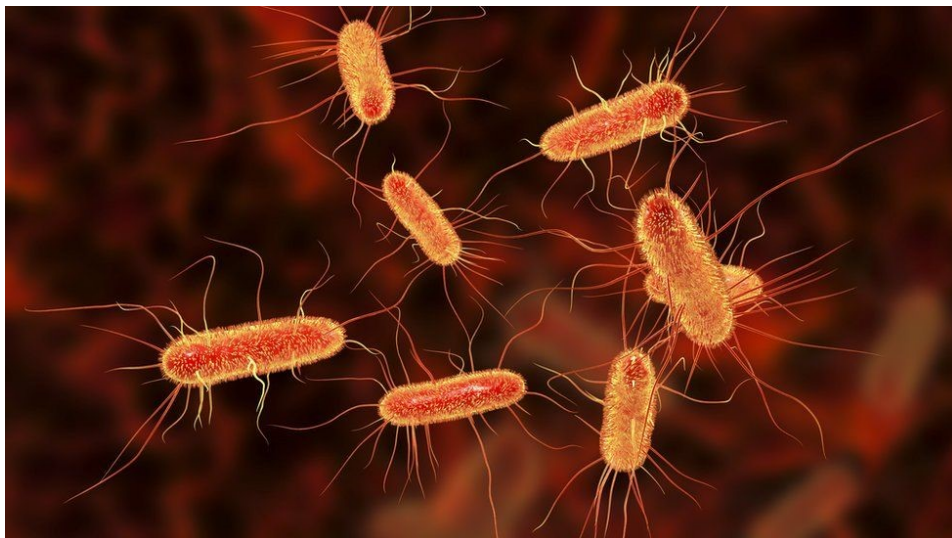
Feeding dairy cows with feed contaminated with mycotoxins can lead to a reduction in milk production. Milk quality may also deteriorate due to an adverse change in milk composition and mycotoxin residues, threatening the innocuousness of dairy products. Dairy farmers should therefore have feed tested regularly, consider masked mycotoxins, and take action. EW Nutrition's [MasterRisk tool](#) provides a risk evaluation and corresponding recommendations for the use of [products](#) that mitigate the effects of mycotoxin contamination and, in the end, guarantee the safety of all of us.

# The hidden danger of endotoxins in animal production



Find out more about endotoxins [here](#)

**Find out why LPS can cause endotoxemia and how intelligent toxin mitigation solutions can support endotoxin management.**



*Each E. coli bacterium contains about 100 lipopolysaccharides molecules in its outer membrane*

Lipopolysaccharides (LPS) are the major building blocks of the outer walls of Gram-negative bacteria. Throughout its life cycle, a bacterium releases these molecules, which are also known as endotoxins, upon cell death and lysis. The quantity of LPS present in Gram-negative bacteria varies between species and serotypes; [Escherichia coli, for example, contain about 100 LPS/bacterial cell](#). When these are released into the intestinal lumen of chickens or swine, or in the rumen of polygastric animals, they can cause

serious [damage to the animal's health and performance](#) by over-stimulating their immune system.

# How lipopolysaccharides cause disease

LPS are rather large and structured chemical molecules with a weight of over 100,000 D. They are highly thermostable; boiling in water at 100°C for 30 minutes does not destabilize their structure. LPS consist of three chemically distinct sections: a) the innermost part, lipid A, consisting mostly of fatty acids; b) the core, which contains an oligosaccharide; and c) the outer section, a chain of polysaccharides called O-antigen (Figure 1).

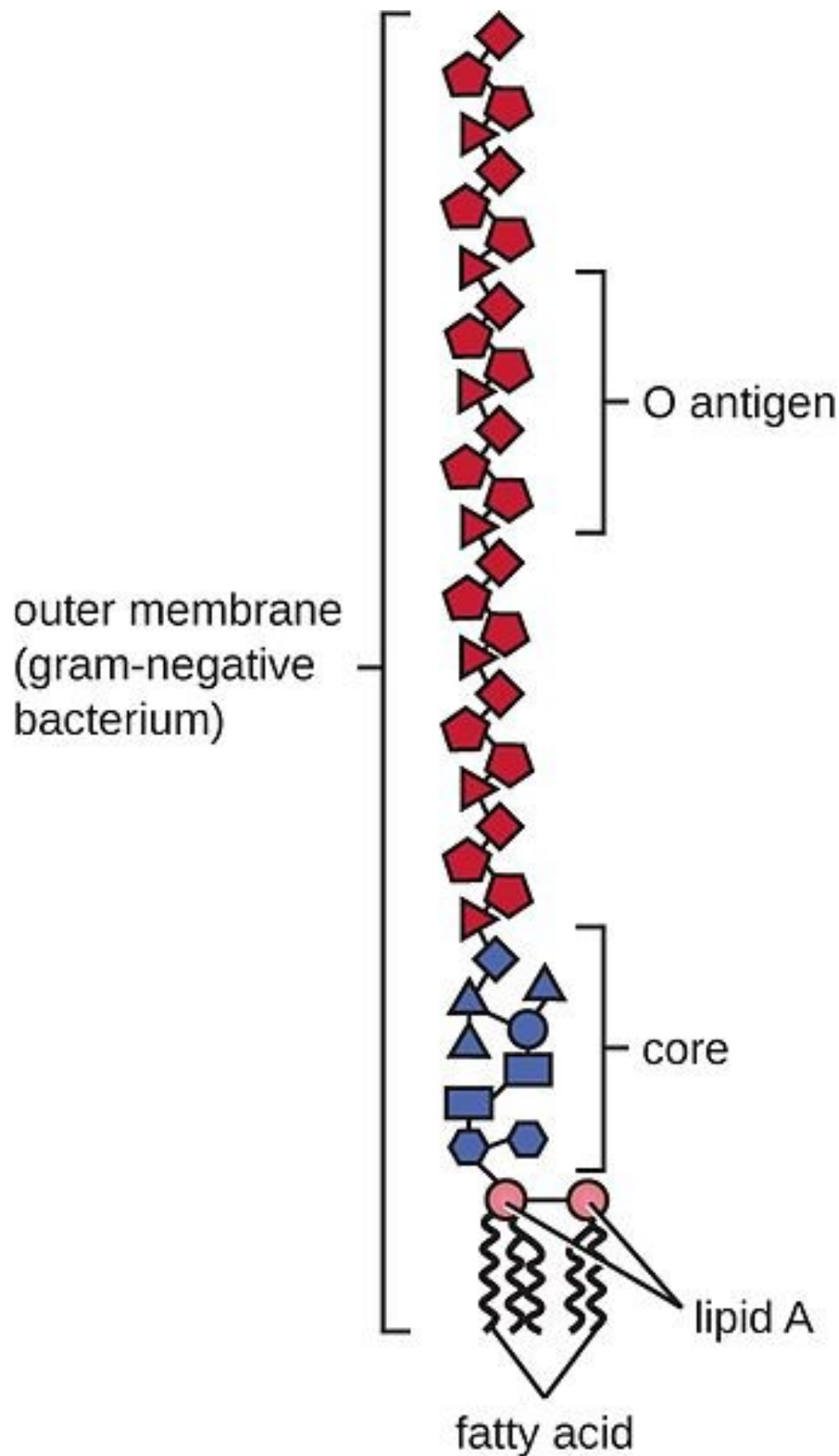


Figure 1: Structure of an LPS

The toxicity of LPS is mainly caused by lipid A; however, both lipid A and O-antigen stimulate the immune system. This happens when the LPS pass the mucosa and enter the bloodstream or when they attack the leukocytes.

The intestinal mucosa is the physical immune barrier that protects the microvilli from external agents (bacteria, free LPS viruses, etc.). Despite its strength (the thickness, for example, amounts to  $\approx 830 \mu\text{m}$  in



the colon and  $\approx 123 \mu\text{m}$  in the jejunum), vulnerable points exist (cf. [Zachary 2017](#)).

LPS can easily come into contact with the cells of the *lamina propria* (a layer of connective tissue underneath the epithelium) through the microfold (M) cells of the Peyer's patches (which consist of gut-associated lymphoid tissue). The M cells are not covered by mucus and thus exposed.

Secondly, LPS can also pass through the mucosa, where they become entangled in this gelatinous structure. There, they come into contact with the lymphocytes or can reach the regional lymph nodes through the afferent lymphatic vessels.

Thirdly, LPS might affect the tight junctions, the multiprotein complexes that keep the enterocytes (cells that form the intestinal villi) cohesive. By destabilizing the protein structures and triggering enzymatic reactions that chemically degrade them, LPS can break the tight junctions, reaching the first capillaries and, consequently, the bloodstream.

The presence of [endotoxins](#) in the blood, endotoxemia, can trigger problematic immune responses in animals. An innate immune stimulation leads to an increase in the concentration of pro-inflammatory cytokines in the blood and, consequently, to an induced febrile response in the animal: heat production increases, while the available metabolic energy decreases. As a result, performance suffers, and in the worst-case scenario, septic shock sets in. Furthermore, when LPS compromise intestinal integrity, the risk of secondary infections increases, and production performance may decline.

## LPS' modes of action

How does all of this happen? The physiological consequences of endotoxemia are quite complex. Simplified, the immune system response to LPS in the blood takes three forms:

- The stimulation of **TLR4** (toll-like receptor 4) induces monocytes and macrophages to secrete critical pro-inflammatory cytokines, primarily interleukin (IL) IL-1 $\beta$ , IL-6, IL-8, and tumor necrotic factor (TNF)  $\alpha$  and  $\beta$ . TLR4 is a structure on the cell membrane of mainly macrophages and leukocytes, which is activated by the LPS-binding protein (LBP).
- The **complement cascade** constitutes about 10% of plasma proteins and determines the chemotaxis and activation of leukocytes. It can form a membrane attack complex (MAC), which perforates the membranes of pathogenic cells, enabling lysis.
- The **Hagemann factor**, also known as coagulation factor XII: once stimulated by LPS, it initiates the formation of fibrin (through the intrinsic coagulation pathway), which might lead to thrombosis. The Hagemann factor directly stimulates the transformation of prekallikrein to kallikrein (enzymes involved in regulating blood pressure).

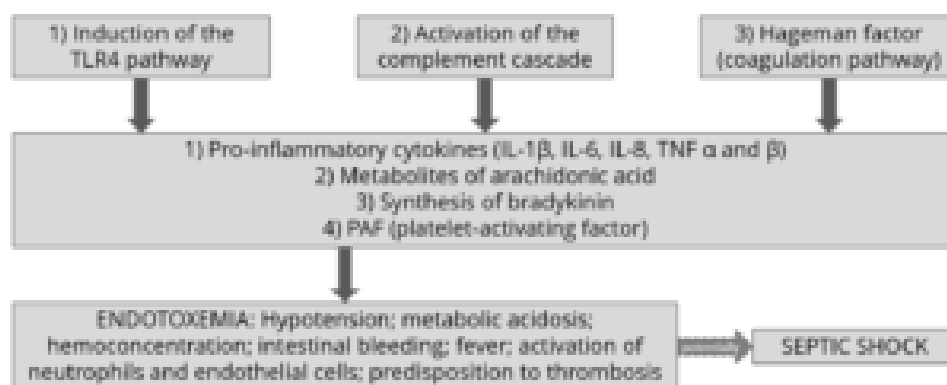


Figure 2: How LPS leads to endotoxemia – 3 modes of action

These three modes of action of inflammatory stimulation lead to important physiological reactions:

- **Pro-inflammatory cytokines** (see above) modulate the functional expression of other immune cell types during the inflammatory response;
- **Metabolites of arachidonic acid** (prostaglandins, leukotrienes, and lipoxins), intra- and extracellular messengers that influence the coagulation cascade;

- Synthesis in the blood of **bradykinin**, a peptide responsible for the typical symptoms of inflammation, such as swelling, redness, heat and pain;
- **PAF** (platelet-activating factor), which creates inflammatory effects through narrowing of the blood vessels and constriction of the airways, but also through the degranulation of leukocytes.

The symptoms of endotoxemia are: hypotension, metabolic acidosis, hemoconcentration, intestinal hemorrhage, fever, activations of neutrophils and endothelial cells, and predisposition to thrombosis.

In case of a progression to septic shock, the following sequence takes place:

- 1) Reduction in blood pressure and increased heart rate (hemodynamic alterations)
- 2) Abnormalities in body temperature
- 3) Progressive hypoperfusion at the level of the microvascular system
- 4) Hypoxic damage to susceptible cells

Up to here, symptoms follow a (severe) endotoxemia pathogenesis. A septic shock furthermore entails:

- 5) Quantitative changes in blood levels of leukocytes and platelets
- 6) Disseminated intravascular coagulation (see Hageman factor)
- 7) Multi-organ failure
- 8) Death of animal

If an animal is continuously challenged with endotoxins, experiences septic shock, or comes close to it, it risks developing LPS tolerance, [also known as CARS](#) (compensatory anti-inflammatory response syndrome). This syndrome essentially depresses the immune system to control its activity. The anti-inflammatory prerogative of CARS is not to interfere directly with the elimination of pathogens but to regulate the “excessive” inflammatory reaction in a hemostatic way. However, this regulation can be extremely dangerous as the syndrome involves a lack of homeostasis control, and an excessive depression of the immune system leaves the organism exposed to the actual pathogens.

## Farm animal research on endotoxemia pathogenesis

Lipopolysaccharides are difficult to quantify in the intestine of a live animal. One way to evaluate a possible endotoxemia is to analyze biomarkers present in the bloodstream. The most important one is the LPS themselves, which can be detected in a blood sample taken from the animal via ELISA. Other biomarkers include pro-inflammatory interleukins, such as TNF  $\alpha$  and  $\beta$ , IL-6 or IL-8, and fibrin and fibrinogen (though they are not specific to endotoxemia). It is vital to carry out a blood sample analysis to deduce a possible endotoxemia from symptoms and performance losses in the animal.

## How the metabolic effects of endotoxemia depress performance

One of the biggest issues caused by endotoxemia is that animals reduce their feed intake and show a poor feed conversion rate (FCR). Why does this happen? The productive performance of farm animals (producing milk, eggs, or meat) requires energy. An animal also requires a certain baseline amount of energy for maintenance, that is, for all activities related to its survival. As a result of inflammation and all those physiological reactions mentioned above, endotoxemia leads to a feverish state. Maintenance needs

to continue; hence, the energy required for producing heat will be diverted from the energy usually spent on producing milk, egg, meat, etc., and performance suffers.

The inflammation response can result in mitochondrial injury to the intestinal cells, which alter the cellular energy metabolism. This is reflected in changes to the levels in adenosine triphosphate (ATP), the energy “currency” of living cells. A study by Li et al. (2015) observed [a respective reduction of 15% and 55% in the ATP levels of the jejunum and ileum of LPS-challenged broilers](#), compared to the unchallenged control group. This illustrates the extent to which animals lose energy while they experience (more or less severe) endotoxemia.

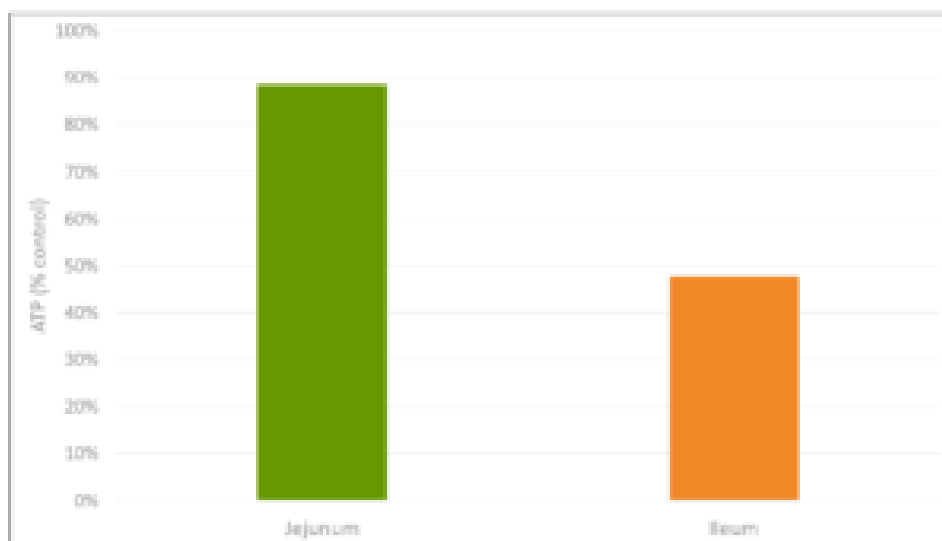


Figure 3: Reduction in ATP level in Jejunum and Ileum in broilers (adapted from [Li et al., 2015](#))

A [piglet study by Huntley, Nyachoti, and Patience \(2017\)](#) took this idea further (Figure 4): 3 groups of 10 Yorkshire x Landrace pigs, weighing between 11 and 25 kg, were studied in metabolic cages and in respiratory chambers. This methodology allows for simultaneous measurement of oxygen consumption, CO<sub>2</sub> production, energy expenditure, physical activity, and feed/water intake. The study found that LPS-challenged pigs retained 15% less of the available metabolizable energy and showed 25% less nutrient deposition. These results show concrete metabolic consequences caused by the febrile response to endotoxemia we discussed above.

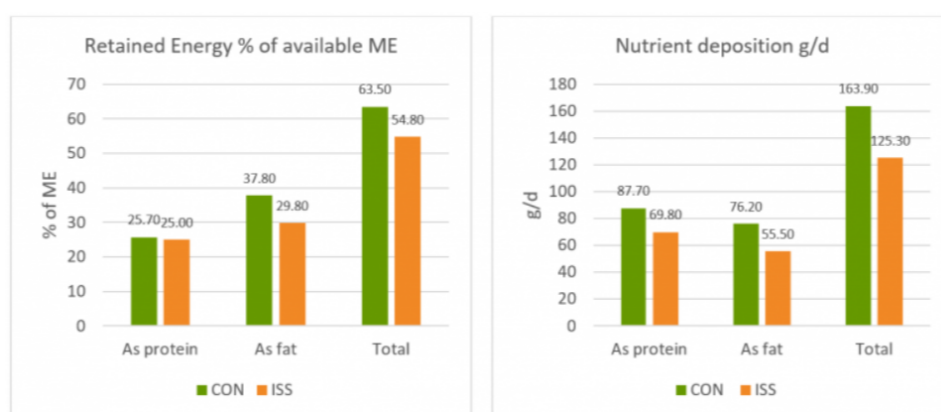


Figure 4: Retained Energy as % of ME intake and nutrient deposition of pigs in metabolic cages (adapted from [Huntley, Nyachoti, and Patience, 2017](#))

Control treatment (CON) = Pigs fed by a basal diet

Immune system stimulation treatment (ISS) = Pigs given LPS (*E. coli* serotype 055:B5) injection

A loss of energy retained due to a reduction in available metabolizable energy leads to losses in performance as the amount of energy available for muscle production and fat storage will be lower. Furthermore, the decrease in feed intake creates a further energy deficit concerning production needs.

A [trial carried out at the University of Illinois](#) examined the effects of repeated injections of 400 µg *E. coli* LPS on chick performance from 11 to 22 days after hatching. The chicks were fed casein-based diets with graded levels of arginine. LPS administration reduced weight gain ( $P < 0.05$ ) and feed intake, and these effects tended to be worse at higher levels of arginine supplementation (Figure 5). The researchers hypothesize that, in response to endotoxin and elevated cytokine levels, macrophages use more arginine to produce nitric oxide, diverting it from protein production for muscle development.

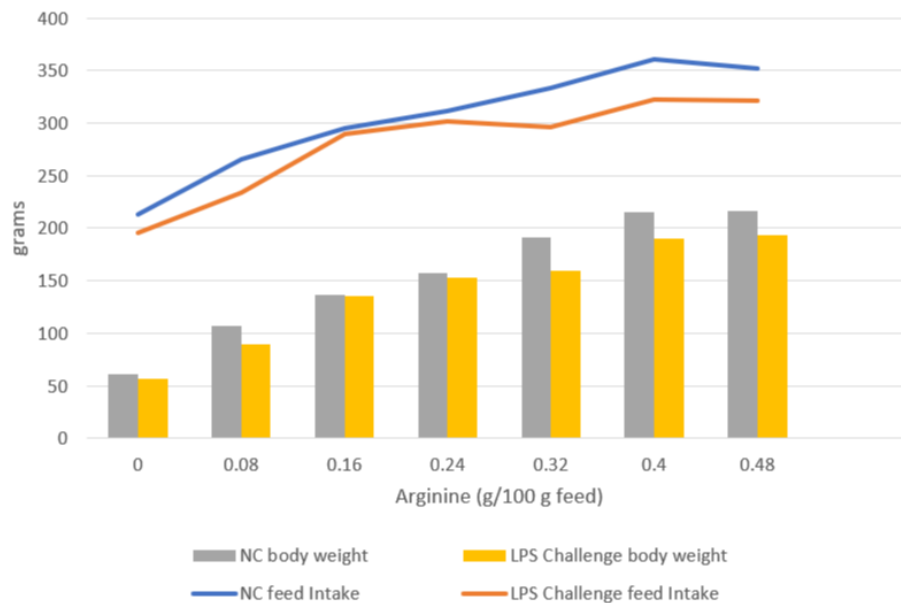


Figure 5: Effects of LPS on feed intake and body weight gain in chicks fed graded level of arginine (based on [Webel, Johnson, and Baker, 1998](#))

NC = negative control

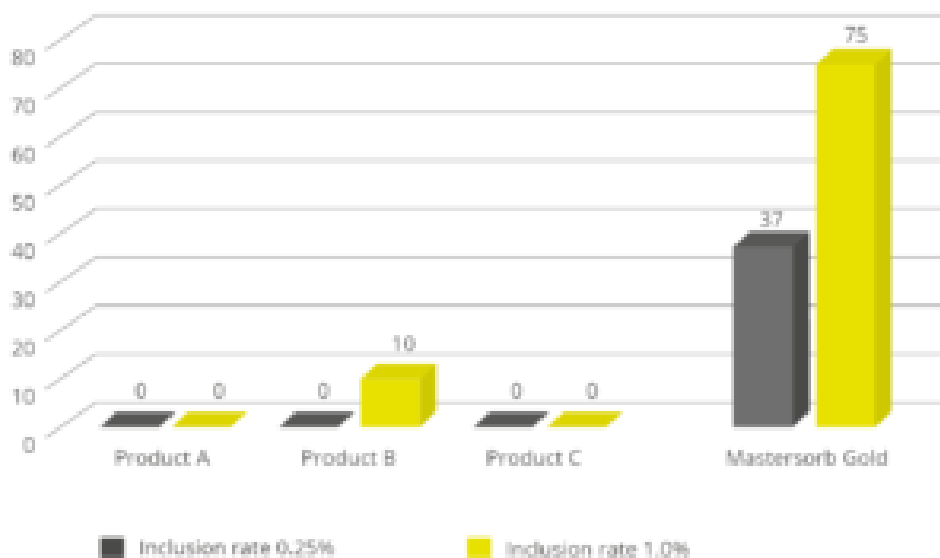
This data on poultry complements the results for swine, again showing that endotoxin-induced energy losses quantifiably depress animal performance even in milder disease cases.

## The way forward: Endotoxin mitigation

Animals suffering from endotoxemia are subject to severe metabolic dysfunctions. If they do not perish from septic shock, they are still likely to show performance losses. Moreover, they are at great risk of immunosuppression caused by the immune system “overdrive.” Effective endotoxin mitigating agents can help to prevent these scenarios.

EW Nutrition’s Mastersorb Gold is not only a [leading anti-mycotoxin agent](#); thanks to its specific components, it effectively binds bacterial toxins. An *in vitro* study conducted at the Hogeschool Utrecht laboratory (part of Utrecht University) evaluated the binding capacity of Mastersorb Gold on LPS compared to three different competitor products. All products were tested at two different inclusion rates. At an inclusion rate of 0.25%, only Mastersorb Gold reduced the toxin load on the solution by 37%. At 1% inclusion, Mastersorb Gold bound 75% of the toxin, while only one competitor product demonstrated any binding (10%).





Lipopolysaccharides are a constant challenge for animal production. The quantity of Gram-negative bacteria in an animal intestine is considerable; therefore, the danger of immune system over-stimulation through endotoxins cannot be taken lightly. Producers need to prioritize the maintenance of intestinal eubiosis in production animals proactively; for instance, through targeted gut health-enhancing additives based on phytomolecules and, possibly, organic acids.

Most importantly, the detrimental impact of LPS can be mitigated by using a high-performance agent such as [Mastersorb Gold](#). To limit losses from an energy point of view yields positive results in terms of production levels and the prevention of secondary infections, preserving animal health and farms' economic viability.

**By Claudio Campanelli, EW Nutrition**

## References

- Adib-Conquy, Minou, and Jean-Marc Cavaillon. "Compensatory Anti-Inflammatory Response Syndrome." *Thrombosis and Haemostasis* 101, no. 01 (2009): 36–47. <https://doi.org/10.1160/th08-07-0421>.
- Huntley, Nichole F., C. Martin Nyachoti, and John F. Patience. "Immune System Stimulation Increases Nursery Pig Maintenance Energy Requirements." *Iowa State University Animal Industry Report* 14, no. 1 (2017). [https://doi.org/10.31274/ans\\_air-180814-344](https://doi.org/10.31274/ans_air-180814-344).
- Li, Jiaolong, Yongqing Hou, Dan Yi, Jun Zhang, Lei Wang, Hongyi Qiu, Binying Ding, and Joshua Gong. "Effects of Tributyrin on Intestinal Energy Status, Antioxidative Capacity and Immune Response to Lipopolysaccharide Challenge in Broilers." *Asian-Australasian Journal of Animal Sciences* 28, no. 12 (2015): 1784–93. <https://doi.org/10.5713/ajas.15.0286>.
- Mani, Venkatesh, James H Hollis, and Nicholas K Gabler. "Dietary Oil Composition Differentially Modulates Intestinal Endotoxin Transport and Postprandial Endotoxemia." *Nutrition & Metabolism* 10, no. 1 (2013): 6. <https://doi.org/10.1186/1743-7075-10-6>.
- Webel, D.M., R.W. Johnson, and D.H. Baker. "Lipopolysaccharide-Induced Reductions in Body Weight Gain and Feed Intake Do Not Reduce the Efficiency of Arginine Utilization for Whole-Body Protein Accretion in the Chick." *Poultry Science* 77, no. 12 (1998): 1893–98. <https://doi.org/10.1093/ps/77.12.1893>.
- Zachary, James F. "Chapter 4 – Mechanisms of Microbial Infections." Essay. In *Pathologic Basis of Veterinary Disease*, 132–241. St Louis, MO: Mosby, 2017. <https://doi.org/10.1016/B978-0-323-35775-3.00004-7>.